Check for updates

Received: 16 February 2021 | Accepted: 17 February 2021

DOI: 10.1002/nau.24658

SOUNDING BOARD

Neurourology Urodynamics ICS SUFU Society of Urodynamics, Female Pelvic Medicine & Urogenital Reconstruction WILEY

An International Continence Society (ICS) report on the terminology for pelvic floor muscle assessment

Helena Frawley[1] | **Beth Shelly**[2,3] | **Melanie Morin**[4] | **Stéphanie Bernard**[5] | **Kari Bø**[6,7] | **Giuseppe Alessandro Digesu**[8] | **Tamara Dickinson**[9] | **Sanchia Goonewardene**[10] | **Doreen McClurg**[11] | **Mohammad S. Rahnama'i**[12,13] | **Alexis Schizas**[14] | **Marijke Slieker-ten Hove**[15,16] | **Satoru Takahashi**[17] | **Jenniffer Voelkl Guevara**[18]

[1]School of Health Sciences, The University of Melbourne, Parkville, Victoria, Australia

[2]Beth Shelly Physical Therapy, Moline, Illinois, USA

[3]Department of Physical Therapy, Saint Ambrose University Davenport, Iowa, USA

[4]School of Rehabilitation Faculty of Medecine and Health Sciences, University of Sherbrooke, Sherbrooke, Québec, Canada

[5]Department of Rehabilitation, Faculté de Médecine, Université Laval, Québec, Quebec, Canada

[6]Department of Sports Medicine, Norwegian School of Sports Sciences, Akershus University Hospital, Oslo, Norway

[7]Department of Obstetrics and Gynecology, Lørenskog, Norway

[8]Academic Department of Obstetrics and Gynaecology, St. Mary's Hospital, Queen Charlotte's and Chelsea Hospital, Imperial College Healthcare NHS Trust, London, UK

[9]Harold C. Simmons Comprehensive Cancer Center, UT Southwestern Medical Center, Dallas, Texas, USA

[10]Department of Urology, The Princess Alexandra Hospital, Harlow, UK

[11]Nursing, Midwifery and Allied Health Professions Research Unit, Glasgow Caledonian University, Glasgow, Scotland, UK

[12]Uniklinik RWTH, University Hospital of Aachen, Aachen, Germany

[13]Society of Urological Research and Education (SURE), Heerlen, The Netherlands

[14]Department of Colorectal Surgery, Guy's and St. Thomas NHS Foundation Trust, London, UK

[15]Department Gynaecology, University of Erasmus, Rotterdam, The Netherlands

[16]Pelvic Floor Physiotherapy, ProFundum Instituut, Dordrecht, The Netherlands

[17]School of Medicine, Nihon University, Tokyo, Japan

[18]Urology Department, University Hospital Fundación Sante Fé de Bogotá, Bogotá, Colombia

Correspondence
Helena Frawley, Melbourne School of Health Sciences, Level 6, Alan Gilbert Building, 161 Barry Street, The University of Melbourne, Victoria 3010, Australia.
Email: h.frawley@unimelb.edu.au

Abstract

Introduction: The terminology for female and male pelvic floor muscle (PFM) assessment has expanded considerably since the first PFM function and dysfunction standardization of terminology document in 2005. New terms have entered assessment reports, and new investigations to measure PFM function and dysfunction have been developed. An update of this terminology

Beth Shelly and Giuseppe Alessandro Digesu: Standardization Steering Committees ICS.

Helena Frawley, Beth Shelly, Melanie Morin, Stéphanie Bernard, Kari Bø, Giuseppe Alessandro Digesu, Doreen McClurg, Mohammad S. Rahnama'i, and Jenniffer Voelkl Guevara: ICS Working Group on Terminology for Pelvic Floor Muscle Assessment.

 © 2021 Wiley Periodicals LLC

was required to comprehensively document the terms and their definitions, and to describe the assessment method and interpretation of the finding, to standardize assessment procedures and aid diagnostic decision making.

Methods: This report combines the input of members of the Standardisation Committee of the International Continence Society (ICS) Working Group 16, with contributions from recognized experts in the field and external referees. A logical, sequential, clinically directed assessment framework was created against which the assessment process was mapped. Within categories and subclassifications, each term was assigned a numeric coding. A transparent process of 12 rounds of full working group and external review was undertaken to exhaustively examine each definition, plus additional extensive internal development, with decision making by collective opinion (consensus).

Results: A Terminology Report for the symptoms, signs, investigations, and diagnoses associated with PFM function and dysfunction, encompassing 185 separate definitions/descriptors, has been developed. It is clinically based with the most common assessment processes defined. Clarity and user-friendliness have been key aims to make it interpretable by clinicians and researchers of different disciplines.

Conclusion: A consensus-based Terminology Report for assessment of PFM function and dysfunction has been produced to aid clinical practice and be a stimulus for research.

KEYWORDS

clinical assessment, diagnosis, muscle dysfunction, pelvic floor

1 | INTRODUCTION

The current terminology used in the assessment and diagnosis of pelvic floor muscle (PFM) function and dysfunction is both diverse and variably defined, with no current consensus which captures, defines, and describes all terms. This document lists and describes terms which are used in the neuro-myo-fascial assessment and diagnosis of the PFM to aid teaching and standardization of terminology in this field. The terminology covers the assessment of both structure and function of the PFM. The pelvic floor structures defined in this document include muscular tissues in the pelvic floor and their neural connections, and the fascial (connective tissue) layers surrounding the PFM fibers/fascicles. In this document, assessment of the PFM is presented according to the perineal and pelvic regions of PFM. While PFM anatomy nomenclature varies according to texts, the following structures are considered to be the muscles that make up the perineum and the pelvic floor/levator ani.[1] The perineal region is divided into the anterior and posterior triangles. The anterior urogenital triangle comprises the superficial urogenital muscles (bulbospongiosus/bulbocavernosus, ischiocavernosus, and the superficial transverse perinei), and the deep urogenital muscles (external urethral sphincter and deep transverse perinei). The posterior (anal) triangle comprises the external anal sphincter. The levator ani is comprised of pubococcygeus (which includes puborectalis, pubovisceralis, pubovaginalis, etc.), iliococcygeus, and ischiococcygeus/coccygeus (considered vestigial). The female and male perineal and PFM, inferior and superior views, are illustrated in Figure 1.

When referencing this document, the reader is asked to keep the term in context with PFM assessment. The PFM terms included apply to adult females and males presenting with different types of pelvic floor disorders. Assessment techniques are undertaken externally (*per perineum* [PP], and internally (*per vaginam* [*PV*] or *per rectum* [*PR*]). Where the definition or description of the term requires modification to differentiate between female *(f)* and male *(m)* assessment, this is indicated.

The search strategy used for this document was performed according to International Continence Society (ICS) Standardisation Steering Committee guidelines. The working group of multinational and

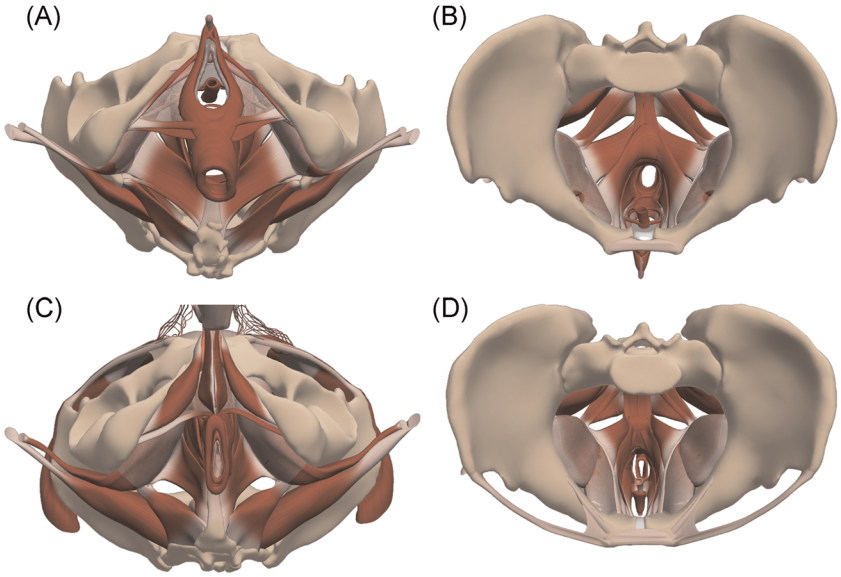

FIGURE 1 (A) Muscles of the female perineum and pelvic floor inferior view (reprinted with permission from Primal pictures[2]). (B) Muscles of the female perineum and pelvic floor superior view (reprinted with permission from Primal pictures[2]). (C) Muscles of the male perineum and pelvic floor inferior superior view (reprinted with permission from Primal pictures[2]). (D) Muscles of the male perineum and pelvic floor superior view (reprinted with permission from Primal pictures[2])

multidisciplinary committee members applied expert opinion to identify existing terms that refer to PFM assessment. Existing published ICS Standardization of Terminology documents were searched and terms added to cover all published terms or in common clinical use that refer to the assessment of PFM function and dysfunction. Inclusion of the final list of terms was achieved via a consensus process, which took place between 2017 and 2019. The final list of terms serves as a reference for future refinement and testing for clinical utility. This document is not a clinical protocol or guideline for how to perform a PFM assessment, it defines and describes terms which may be used in a clinical assessment of PFM function. As such, this document does not include within its scope other important considerations when undertaking a PFM assessment. These include but are not limited to competency of the assessor, clinical reasoning required for diagnostic decision making, protocol when conducting a sensitive examination of an intimate body part, appropriate informed consent, and ethical and legal considerations.[3] Further, only a brief, introductory-level description of how to undertake the test is provided, not a detailed description of the exercise protocol using that tool, with the reader directed to other texts for more detailed description.

The number of total, new, and changed ICS definition terms relevant to PFM assessment are shown in Table 1. If a term does not currently exist in an ICS Standardisation of Terminology document, it is indicated here as a "**NEW**" term. When a term appears in an existing ICS Standardisation of Terminology document, the term definition and description is reproduced here with reference to the original terminology document, to present a complete framework of PFM assessment. When a modification to the existing term occurs, the word "**CHANGED**" is used. If the change is a significant alteration from the existing term, a footnote is used to explain the reason for modification, and a reference to the original term cited. Several of the terms related to ultrasound imaging have been drawn from the AIUM/IUGA practice parameter for the performance of Urogynecological ultrasound examinations document.[4] Similarly, terms in the algometry section already exist in the field of pain science, and terms related to muscle

TABLE 1 Total, new, and changed ICS definition terms

Section	New definitions/ descriptors	Changed definitions/ descriptors	Unchanged definitions/ descriptors	Total
Introduction and symptoms	1	1	0	2
Signs	31	15	12	58
Investigations	80	18	17	115
Diagnoses	7	3	0	10
Total	119 (64%)	37 (20%)	29 (16%)	185

Abbreviation: ICS, International Continence Society.

Box 1 Checklist of PFM clinical assessment, applicable to signs and investigations

Aspect to standardize	Details to record
1. Patient's body position for the PFM assessment	• Lying or upright • If lying, hip/knee flexion, supine, side-lying, or lithotomy • Number of pillows, +/− support from assessor's body • Bladder empty or not
2. Testing of left and right sides of PFM. Symmetry: A measure of comparability of resting tone or shape between left and right sides of the muscle. If examining in side-lying, there will be a gravity effect and the dependent side may have a different feel to the upper side and appear as asymmetrical. This may affect assessor perception of PFM resting tone	Record if symmetry/asymmetry is present at rest and on activity (contraction/relaxation). Rate as: • Symmetry between left and right (on a particular aspect/parameter) • Asymmetry present. Identify what aspect/parameter is asymmetrical, e.g., tone, L<R[15]
3. Amount of pressure (light/moderate/strong) applied during digital palpation tests. Particular care is required when undertaking a PFM assessment in the presence of pelvic floor pain, however, even in an asymptomatic individual, the assessor may provoke pain or discomfort due to undue pressure applied during palpation or application of an instrument	• If discomfort or pain is provoked, note pain location, intensity, duration (transient or persistent), if it reproduces the pain the patient complains of, and if referral of pain occurs to other locations
4. Number of digits (and which digit) used during digital palpation	• For single digit examination (*PV* or *PR*), usually the index finger is used • For two-digit examination (*PV*), usually the index and middle digits are used
5. Orientation (e.g., lateral placement or posterior midline) and depth of examining finger(s) during internal digital palpation examination[vi]	• The examining finger must be as close as possible to the PFM tissue to assess PFM response • When performing a *PV* examination, assessor decision as to which side or midline to examine will be determined by lumen capacity, presence of tenderness or defect and presence of firm stool within the rectum • When performing a *PR* examination, external anal sphincter and puborectalis strength should be assessed separately • Record depth of insertion of examining finger for differential assessment of perineal versus levator ani muscle layers. Further identification of individual muscles is not possible in all individuals
6. Instruction to perform a maximum voluntary contraction (MVC)	• Provide details of the instruction (wording, number of repetitions, and rest between repetitions) to ensure the test can be reproduced as an MVC
7. Contraction of muscles other than those of the pelvic floor	• if this is perceived to influence the PFM assessment, an attempt to minimize this should be made unless the purpose is to assess function of the other muscle. • List specific muscle, such as abdominal, hip adductor, etc.

Abbreviations: L, left; MVC, maximum voluntary contraction; PFM, pelvic floor muscle(s); *PR*, *per rectum*; *PV*, *per vaginam*; R, right.

TABLE 2 External assessment *per perineum*: Visual observation

Test	Rating
Tests of visual observation per perineum *at rest*	
2.1.1 Perineal skin assessment: Assessment of the perineal skin to note presence of: scars, lesions (e.g., fissure), trophic changes/atrophy, color, erythema, swelling, and other conditions which could affect the function of the PFM **(NEW)**	• Normal skin • Altered (detail the observation including extent of alteration)
2.1.2 Perineal body length (*f*): Distance from posterior margin of vestibule to anterior anal verge[18]	• State if < or >3 cm[19,20]
2.1.3 Perineal body position at rest: Relationship of the position of the perineal body to ischial tuberosities[a] **(*NEW*).** Palpate ischial tuberosity and visually estimate the relationship	• **2.1.3.1 Descended perineum**: Perineal body rests below the plane of the ischial tuberosities[21]**(NEW)** • Normal: At or slightly above the level of the ischial tuberosities • Elevated: Significantly indrawn perineum at rest
2.1.4 Introital gaping: Opening, or noncoaptation of vagina at rest. **(NEW)** If the introitus is not visible at rest the labia may need to be parted	• Present • Absent
2.1.5 Keyhole deformity at anus: Characteristic posterior midline furrow deformity. This complication is seen when the anus is inspected by gently retracting the buttocks laterally. The anus is no longer slit-like, but appears in shape like a keyhole[22]**(NEW)**	• Present • Note location of deformity with reference to a clock-face (where 12 o'clock is anterior/ventral) • Absent
2.1.6 Anal gaping: Noncoaptation of anal mucosa at rest[11]	• Present • Note location of deformity with reference to a clock-face • Absent
Tests of visual observation per perineum *with a PFM contraction*	
2.1.7 Voluntary contraction of the PFM: Self-initiated activation of the PFM. **(CHANGED)**[23] Contraction of the bulbospongiosus/bulbocavernosus, ischiocavernosus, transverse perinei muscles may be observed[b]. The assessor may need to gently move the external genitalia (parting of the labia, lifting of the scrotum to one side) to effectively visualize the perineal response	• Present • Uncertain • Absent • Response can be further described according to perineal movement observed: • **2.1.7.1 Perineal elevation**: Inward (ventrocephalad) movement of the vulva (*f*), perineum, and anus[11,24] = normal finding • No change • Sex-specific changes on perineal elevation: • *f*: closure of the urethral meatus ("wink"); a clitoral "nod" • *m*: Closure of the anus, cephalad testicular lift and penile retraction (the shaft of the penis draws in[c])[25–27] • **2.1.7.2 Perineal descent**: Dorsocaudal movement of the perineum, or anus 1 cm or greater beyond resting level **(CHANGED)**[24d]
2.1.8 Relaxation of the PFM: Return of the perineum to its original resting position following the voluntary contraction **(NEW)**	If present, rate as: • Yes: Full relaxation visible directly after instruction; normal finding[15] • Partial or delayed relaxation[15] • **2.1.8.1 Nonrelaxing PFM**: No relaxation visualized of the PFM **(CHANGED)**[23e].
Tests of visual observation per perineum *with an increase in intra-abdominal pressure (IAP)*	
2.1.9 Perineal movement with a sustained increase in IAP: Direction of perineal movement during a sustained effort[f]. **(NEW).** As there may be a difference in PFM response to	• Perineal elevation (see 2.1.7.1)[g] • No change • Perineal descent (see 2.1.7.2)

(Continues)

TABLE 2 (Continued)

Test	Rating
bearing down versus valsalva,[28] it is important to state exact test instruction depending on the test, as the observed response may vary • **2.1.9.1 Valsalva**: Forceful exhalation against a closed mouth, glottis, and nose.[28] **(NEW)** Valsalva has been shown to result in an increase in IAP and usually an increase in PFM activation[28] • **2.1.9.2 Bearing down (as if defecating)**: A strain or push, which results in an increase in IAP which exerts a downward pressure, usually accompanied by PFM relaxation **(NEW)**	• **2.1.9.3 Excessive perineal descent with bearing down: Movement of the perineum 3 cm or more below resting position**[29h] **(NEW)**
2.1.10 Perineal movement with rapid increase in IAP: direction of perineal movement during a rapid increase in IAP such as coughing, lifting, throwing. **(NEW)** Clarify if the patient is instructed to contract PFM before cough to differentiate voluntary (learned) response from an involuntary response (un-learned)	• Perineal elevation (see 2.1.7.1)[23i,j] • May be due to: • Voluntary contraction (see 2.1.19)—precontraction may be a learned response[k] • **2.1.10.1 Involuntary contraction**: A contraction which occurs reflexively or automatically, without volition or conscious control. Observe this response before instructing in a voluntary pre-contraction to differentiate from the voluntary pre-contraction response. **(CHANGED)**[23] • No change • Perineal descent[l]

Abbreviations: *f,* female; IAP, intra-abdominal pressure; *m,* male; PFM, pelvic floor muscles.

[a]Visual observation of the exact position maybe influenced by variations in adipose tissue over the ischial tuberosities.[21,29–31]

[b]5As the levator ani are likely to be co-contracting with the superficial PFM, the observed response is unlikely to be due to the superficial PFM layer alone, as the levator ani contraction is likely to be contributing to the observed response.

[c]These movements may be observed alongside perineal elevation and may be better visualized in standing than supine. These observations to be checked against movement of the scrotum and the whole penis.

[d]Modification: The word "excessive" has been removed from the previous definition[24] as some downward movement of the perineum is normal with coughing or bearing down such as in defecation.

[e]The term "nonrelaxing PFM"[23] was previously used as a diagnosis, however, this term describes a sign, and is not recommended to be used as a diagnosis. This sign may be combined with symptoms to inform a clinical diagnosis.

[f]The term "involuntary relaxation" is not recommended to define perineal movement as it not possible to determine if the downward PFM movement is related to voluntary muscle relaxation or passive elongation of noncontractile tissue.

[g]Some patients will not allow full relaxation during assessment for fear of releasing gas or urine, therefore may voluntarily contract during this test.

[h]Adipose tissue at the ischial tuberosities will affect the measurement.[29]

[i]Perineal elevation with cough is expected but not always present.

[j]Messelink et al.[23] described the response of perineal elevation to a rapid increase in IAP as the test for an involuntary contraction. However, it is not possible to say if this is an involuntary or reflex activation of muscle spindles resulting in a contraction, or a voluntary pre-contraction of the PFM before increased IAP. Strategies may differ or be combined.[28]

[k]This manoeuvre is also called "the knack."[32]

[l]A small degree of descent may be normal.[33]

function exist in the field of exercise physiology, and so forth. These terms are labeled **NEW** for the purposes of this document however we acknowledge that these terms are already published and may be in widespread use.

There is a plethora of existing terms and conceptual and operational definitions related to PFM function and dysfunction.[5] Saltiel et al.[5] observed inconsistency and redundancy in PFM function terminology and suggested that a further consideration of PFM function terms relevant to research and to clinical practice is required.[5] A mapping of PFM function terms to the WHO International Classification of Functioning, Disability and Health (ICF) framework has been recently proposed,[6] leading to a list of the most frequently used terms.[7] In this paper, we define the assessment term, describe the application of the test and interpretation of its finding within a framework of diagnostic decision making and clinical reasoning. This follows the usual order of assessment undertaken by a clinician or researcher (referred to in this paper as an "assessor"), leading to a presumed diagnosis and formulation of a treatment plan, to help guide clinical practice.

TABLE 3 External assessment *per perineum*: Digital palpation

Test	Rating
Tests of digital palpation per perineum *at rest*	
2.1.11 Sensation: Test for presence, absence or altered quality of sensation in dermatomal distributions especially S2-4. May include light touch, blunt, sharp, pain, cold, vibration modalities **(NEW)**	• Allodynic, anesthetic, dysesthetic, hyperalgesic, hyperesthesic, hypoalgesic, hypoesthesic, paresthesic, neuralgic[34]
2.1.12 Perineal scarring: Presence of scar tissue on perineum (**NEW**). Using a finger-tip, attempt to slide the scar in all directions. Assess for adhesion or lack of skin mobility over underlying tissue[a]	• Present • Degree of healing • Location of scar in relation to vulva/scrotum or anus • Location of adhesion • Extent/magnitude of Scar mobility[35] • Absent
2.1.13 Tone: state of the muscle, usually defined by its resting tension, clinically determined by resistance to passive movement.[24] The recommended position of the examining digit (s) is to place the palmar surface of the examining finger on the ischiocavernosus, bulbospongiosus (*f*)/bulbocavernosus (*m*) or transverse perineal muscle belly at the thickest portion of the muscle belly, *per perineum*. Pressure or stretch is applied perpendicular to the muscle fibers to assess tone. Tone is described in more detail in 2.2.3	• Normal • Decreased tone (see 2.2.3.4) • Increased tone (see 2.2.3.5)
2.1.14 Tenderness: Sensation of discomfort with or without pain; discomfort elicited through palpation of any tissue indicates unusual sensitivity to pressure or touch.[24] May be generalized within a muscle **2.1.14.1 Tender point**: Area of localized tenderness occurring in muscle, muscle-tendon junction, bursa, or fat pad **(CHANGED)**[24b]	• Note location of pressure application • Note location of pain (where pressure applied, or if pain referral present, note location of pain referral) • Rate severity of pain on a numeric rating scale (NRS) 0–10[36]
2.1.15 Pudendal nerve neurodynamics: Neurodynamic assessment evaluates the length and mobility of the nerve to assess neurogenic origin of pain[37]**(NEW)**. Tension is applied to the nerve or specific component of the nerve by lengthening the nerve or by distracting imposing tissues.[37] Specific components of the pudendal nerve can be put under tension such as the inferior rectal branch, the dorsal branch and the perineal branch	• Positive: If pain, sensation of burning or stabbing are experienced in the distribution of the nerve. This assessment can be uncomfortable in asymptomatic individuals, however, reproduction of patient's pain is suggestive of a neurogenic origin of pain • Negative
2.1.16 Cotton swab test (*f*)[c]: A test for vestibular tissue sensitivity. **(NEW)** The test is performed with a cotton swab moistened with water or lubricating gel. Gentle pressure is applied to the following areas of the vaginal vestibule[d] in random order: 12:00, and quadrants 12–3:00, 3:00–6:00, 6:00–9:00, 9:00–12:00[e]	• Positive if gentle pressure reproduces patient's pain • Report location of pain and severity on NRS 0–10[36] • Negative
Tests of digital palpation per perineum *for sacral reflex function*	
2.1.17 Sacral reflex testing: a measure of the involuntary function of sacral nerves. **(CHANGED)**[12f] Tests are described below.	• Present: Observation of anal sphincter contraction. Indicative of intact spinal reflex arcs (S2–S4 spinal segments) with afferent and efferent nerves through the pudendal nerve[38] • Absent: No sphincter activity
2.1.17.1 Bulbocavernosus reflex (*f*): A reflex contraction of the anal sphincter and bulbocavernosus in response to squeezing the clitoris **(CHANGED)**[12]	• Present • Absent
2.1.17.2 Bulbospongiosus reflex (*m*): A reflex contraction of the striated muscles of the pelvic floor (anal sphincter) including	• Present • Absent

(Continues)

TABLE 3 (Continued)

Test	Rating
bulbospongiosus muscles that occurs in response to various stimuli in the perineum or genitalia. Most commonly tested by placing a finger in the rectum and then squeezing the glans penis[39]	
2.1.17.3 Anal reflex: A reflex contraction of the anal sphincter in response to a painful pin prick delivered to the perianal skin[12]**(CHANGED)**[g]	• Present • Absent
Tests of digital palpation per perineum *with PFM contraction*[h]	
2.1.18 Voluntary contraction of the PFM: Self-initiated activation of the PFM (same term as 2.1.7). Each of the bulbospongiosus/bulbocavernosus, ischiocavernosus, and transverse perinei muscles may be palpated separately. The assessor may need to gently move the external genitalia (parting of the labia, lifting of the scrotum to one side) to effectively palpate the perineal response	• Present • Absent • Uncertain

Abbreviations: *f,* female; *m,* male; NRS, numeric rating scale; PFM, pelvic floor muscles.

[a]Adherent skin could impact function of PFM beneath the scar.

[b]Tender points (2.1.15.1) differ from trigger points (see 2.2.3) therefore the terms should not be used interchangeably.[40]

[c]This test is also referred to as the "Q Tip test." "Cotton swab" is preferred to avoid proprietary names.

[d]Excessive pressure could provoke underlying structures (such as the PFM) misleading the report of pain to vestibular tissues.

[e]Examination tip: In patients with high irritability, it is recommended to test the most severe pain area last to avoid an amplified response due to carry-over irritation as the test progresses.[41,42] In addition if an area provokes increased pain, it is important to wait for the pain to subside before testing other locations.

[f]This term is listed as a modification of the term in Rogers et al.[12]

[g]In contrast to the bulbocavernosus reflex the anal reflex is a nociceptive reflex and the correct stimulus is painful. If a single stimulus does not activate the reflex, several pricks in a fast sequence should be delivered. It is often difficult to elicit in the elderly, and it should not be declared absent if only a single stimulus is used. A "voluntary" movement away from the (painful) stimulus (pin prick) can usually be interpreted correctly. The patient should be told that painful stimuli are going to be delivered, and usually they can "keep still" and only the reflex contraction of the anal sphincter is observed. It is often absent even in patients without a neural lesion.

[h]Some of the tests performed in the external examination section may be repeated during the internal examination.

This process includes the use of a patient's history, patient-reported symptoms/outcomes, and information gained from clinical signs and the results of investigations. It is important to recognize that neuro-musculoskeletal structures beyond the PFM muscles (e.g., intra- and extra-pelvic muscles, the bony pelvis and pelvic girdle joints, and central nervous system factors) may impact on PFM function, however, terminology relating to the assessment of these structures and systems is beyond the scope of this paper.

We hope the terminology sited within this framework provides greater clarity and aids standardization of the usage of these terms. Where possible, the sequence of the terminology follows this order: the region of assessment, the type of evaluation being undertaken, the name ("term") of the test/assessment being undertaken, the definition of that term, the description of how that assessment method is undertaken, how the assessment is rated and the terminology used to describe the finding.

Limitations

Normative data of PFM structure and function are lacking for the majority of PFM terms, which hinders the ability to rate or interpret the finding as "normal" or "abnormal." In addition, due to the lack of known validity, reliability, and responsiveness to change and diagnostic test accuracy (sensitivity, specificity) of many of the commonly used PFM clinical assessment methods, investigations, and diagnoses, the clinical utility of these terms remains unknown. Therefore, this document is not intended to be an evidence-based recommendation of which tests should be included in a PFM assessment; rather our aim is to define and describe currently used terms, which subsequent research may recommend for or against using in PFM assessment. Evidence to support or abandon the use of any of these terms and assessment methods is eagerly awaited. In the meantime, we advise assessors to exercise great caution in their interpretation of clinical findings, especially those measured with visual observation, digital palpation, and outputs of some of the available assessment tools, as despite their widespread clinical usage, these tests can yield subjective and highly variable findings. Due to the abundance and variety of terms used in the literature related to methods and techniques of measurements, word count has necessitated that this document describes only the most frequently published, or methods and techniques using that particular tool in common clinical usage.

TABLE 4 Tests of digital palpation *per vaginam*/*per rectum*, resting state

Test	Rating
2.2.1 Sensation: test for presence, absence, or altered quality of light touch sensation as for 2.1.12	• Present • Absent • Altered: increased or decreased
2.2.2 Presence of scarring: Presence of scar tissue along vaginal walls or apex. **(NEW)**. Using a finger-tip, attempt to slide the scar in all directions. Assess for adhesion or lack of mucosal/vaginal wall mobility over underlying tissue[a]	• Present • Location of adhesion • Degree of healing • Extent/magnitude amount of scar mobility • Absent
2.2.3 Tone: see 2.1.13. The recommended position of the examining digit(s) is to place the palmar surface of the examining finger on the levator ani, *PV*, or *PR*. Pressure or stretch is applied perpendicular to the muscle fibers to assess tone Further details regarding terminology and assessment of muscle tone are provided in text section 2.2.3	• Normal • Decreased tone (see 2.2.3.4) • **Increased tone (see 2.2.3.5)**
2.2.4 Fasciculation: individual brief twitches in a muscle. They may occur at rest or after muscle contraction and may last several minutes[24,43]	• Present • Absent
2.2.5 Tenderness: See 2.1.15 and 2.1.15.1	See 2.1.15 and 2.1.15.1
2.2.6 Pudendal nerve provocation test: Palpation of the pudendal nerve to reproduce patient's pain if entrapment is suspected. The nerve may be palpated at the ischial spine, sacrospinous and sacrotuberous ligaments, or pudendal canal[44,45] **(NEW)**	• Positive (pain response) • Negative
Per rectum only	
2.2.7 Digital rectal examination (DRE)[b]: Palpatory examination of the anorectal tissues[c] **(CHANGED)**[39]	
2.2.8 Palpable anal sphincter gap (PR): a clear "gap" in the anal sphincter on digital examination indicates an anal sphincter tear **(CHANGED)**[11d]	• Present • Absent • Note location

Abbreviations: NRS, numeric rating scale; PR, *per rectum*.

[a]Adherent skin could impact function of PFM beneath the scar.

[b]Despite the name (DRE), the purpose of the examination is usually to assess anal canal tissue, not rectal tissue.

[c]DRE may be less useful in male urinary dysfunctions where the urethral sphincter, inaccessible to DRE, has a more important role.[46]

[d]An assessment can be made of a palpable anal sphincter gap to assess if there has been previous obstetric or surgical damage.[11]

With these limitations in mind, we recommend rating of PFM symptoms as present or absent; if present, a severity and/or bother scale can be added to aid reassessment in response to an intervention. Some of the signs and investigations terms have rating scales associated with their method and these should be used; if not, we recommend that assessors employ linear measurements (mm/cm) or specify ISI international units of measurement (e.g., s = seconds) where applicable to aid objectivity of the assessment method. If "normal" observations or values are not known, we recommend avoidance of the term "abnormal" or suggestion of pathology or disorder, as this cannot be confirmed with current knowledge. When using assessment methods which measure on a continuous scale but lack reference data of a "normal" value, the terms "increased"/"elevated"/"higher"/"faster," or "decreased"/"reduced"/"lower"/"slower" may be used as this is the limit of our

TABLE 5 Tests of digital palpation *per vaginam* only with the PFM in a resting state

Test	Rating
2.2.9 Flexibility of the vaginal opening: The capacity of the vaginal opening to expand in response to stretching. **(NEW)** Assessed by separating index and middle finger in the medio-lateral direction.[47] Digital assessment of the vaginal opening is likely to represent the width of the levator hiatus[a]	• Estimate the number of finger widths between the muscle bellies • Can be converted to cm width for the recording from that assessor
2.2.10 Levator injury/avulsion: A discontinuity of the levator muscle at its attachment to the inferior pubic ramus. **(NEW)** Discontinuity may represent a partial tear, full tear, or thinning. Test for levator injury/avulsion: palpation of levator tissue, by placing finger(s) between the side of the urethra and the edge of the muscle measured on each side. The test is performed at rest and confirmed by asking the patient to contract and feeling for the edge of the contractile tissue of the levator muscle	• Absent: Palpable PFM contraction next to the urethra on the inferior pubic ramus • Present: A distance of >3.5 finger widths between the two sides of puborectalis muscle insertion on PFM contraction[24b] • Rate number of finger widths palpable in the gap. • Several rating scales exist[48,49]

Abbreviation: PFM, pelvic floor muscles.

[a]Levator hiatus may be better measured with instruments (see Section 3).

[b]<3.5 cm may represent a partial avulsion, however, digital palpation cannot reliably determine this distance of discontinuity

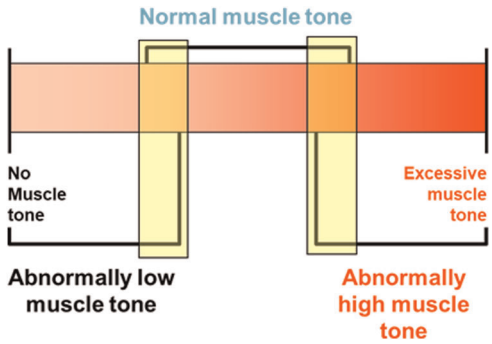

FIGURE 2 Spectrum of muscle tone (adapted from Allen and Widener 2009, with permission[50])

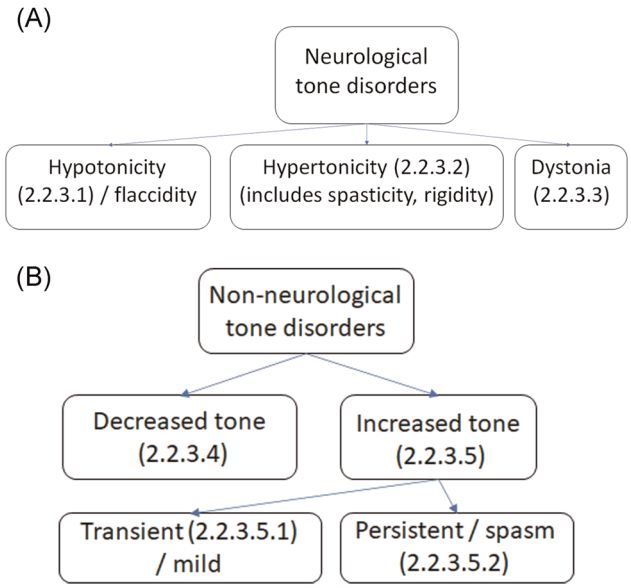

FIGURE 3 Terms for disorders of tone due to a neurological disorder (A) and a nonneurological disorder (B)

certainty at this point in time. Nevertheless, we acknowledge the subjectivity of these relative rating terms.

2 | SECTION 1: SYMPTOMS

This section lists symptoms a patient may use to describe a sensation which could be related to a disorder of PFM structure or function. We recommend the assessor accurately documents the term the patient uses to describe the symptom, rather than an assessor-interpreted term, as symptoms may be used as a patient-reported outcome. A patient-reported outcome is any report of the status of a patient's health condition that comes directly from the patient, without interpretation of the patient's response by an assessor.[8,9]

PFM-related symptoms are divided into sensory and motor categories. PFM-related symptoms may coexist with symptoms of pelvic floor disorders such as urinary incontinence, voiding dysfunction, fecal incontinence, defecatory dysfunction, sexual dysfunction, or pelvic organ prolapse, as well as coexist with other disorders of neuro-musculo-skeletal structures in the pelvis or spine[i]: the assessor should document the patient's symptoms and identify which of these s/he considers to be related to the PFM. Examples are provided of words a patient may use to describe their symptoms to the assessor. These words are not specific to neural or myofascial structures in the PFM—they are generic and may be used by a patient to describe altered sensation in any body part—and are therefore not different to standard definitions of these terms in English dictionaries. For this reason, definitions are not provided for these terms in this document, as they are not PFM-specific. The likely exception

TABLE 6 Tests of digital palpation *per vaginam*/*per rectum* on PFM contraction

Test	Rating
2.2.11 Voluntary contraction of the PFM: Self-initiated activation of the PFM (same term as 2.1.7). A contraction is felt as a tightening, lifting, and squeezing action under the examining finger. Technique:	Presence of contraction may be rated as:
• The recommended position of the examining digit(s) to assess levator ani contraction (*PV*) unilaterally is to place the palmar surface of the examining finger on the lateral levator ani muscle belly surface or "edge," which may be identified by asking the patient to contract then relax • The recommended position of the examining digit to assess anal sphincter and puborectalis muscle function (PR) is to place the palmar surface of the well-lubricated examining finger at the anal verge initially, wait for relaxation of EAS, then insert gently along the posterior wall of the anal canal.[60] Once anal sphincter function is assessed the examining digit remains pressed against the posterior wall and is inserted slowly into the rectum, passing over puborectalis at the anorectal junction	• No contraction • correct contraction (cephalad and ventral movement) • Contraction only with help from other muscles • Uncertain • Straining[61] Absent: **2.2.11.1 Noncontracting PFM**: During palpation there is no palpable voluntary or involuntary contraction of the PFM[23a]
2.2.12 Digital muscle test (DMT): A test to evaluate PFM strength **(NEW)**. **2.2.12.1 Strength**: Force-generating capacity of a muscle. Usually expressed as a maximum voluntary contraction measurement (MVC).[24] A manual muscle test (MMT) evaluates the strength of a muscle by moving the muscle through its full-range of motion against gravity and then against gravity with resistance.[14] However, because joint range of motion is not being assessed in the pelvic floor and PFM examination is performed with a digit, not a hand, the term DMT is preferred. There are more than 25 published DMT scales[62,63] which provide grade of strength ranging from absence, to weakness to increasing strength	• Commonly used scales include: ICS scale: absent, weak, normal (we propose the word "moderate" instead of normal), or strong[23] • modified Oxford grading scale 0–5[64] • Brink scale[65] grades 3 components (pressure, displacement, and time) on a scale of 1–4 • many others[62,63]
2.2.13 Direction of pelvic floor movement: Direction of pelvic floor movement during voluntary PFM contraction palpated *PV* (on the posterior vaginal wall) or *PR* **(NEW)**	• Pelvic floor elevation: normal finding • Pelvic floor descent: palpation of downward movement of the PFM during attempted PFM contraction • No change
2.2.14 Endurance: Muscular endurance refers to the ability of a muscle or muscle group to perform repeated contractions or to maintain a contraction for a predetermined period of time[66,67] (**CHANGED**)[24]	**2.2.14.1 Fatigue**: A decreased capacity to perform a maximum voluntary muscle action or a series of repetitive contractions. **(NEW)** Fatigue may occur due to central or peripheral mechanisms.[68] A fatigued muscle is unable to continue working even when the type of activity is changed[b] Record the time at which fatigue starts to occur, or the number of contractions in a row before onset of fatigue
2.2.14.2 Sustained contraction endurance test: the number of seconds the patient can hold near maximal or maximal PFM contraction **(NEW)**	• Record number of seconds contraction is sustained at near maximal or maximal intensity
2.2.14.3 Repeatability of contraction: The ability to repeatedly develop near maximal or maximal force determined by assessing the maximum number of repetitions the patient can perform **(CHANGED)**[24c]	• Record number of contractions in a row
2.2.15 Number of rapid contractions performed: The number of repeated, quick MVCs performed **(NEW)**. This can be measured in two ways, according to the instruction:	Use the rating appropriate to the instruction:

(Continues)

TABLE 6 (Continued)

Test	Rating
1. Number of contractions repeated within a specific duration (i.e., a 10-s period[5]) **2.** The elapsed time to perform a pre-specified number of contractions (e.g., 10 s[69])A contraction should comprise an ascending and a descending phase with the PFM force returning to the resting state in between. If the maximal force declines, the assessment ceases	• Record the number of contractions repeated and the duration allowed to perform them • Specify the exact number of contractions to be repeated and record the number of seconds to completion. • Qualitative descriptions can include quality and extent of contraction and relaxation phases
2.2.16 Relaxation postcontraction: Return of the PFM to its original resting tone following the voluntary contraction **(CHANGED)**[23d]. The patient is able to relax the PFMs on demand, after a contraction has been performed. Relaxation is felt as a termination of the contraction	• Yes: Relaxation felt directly after instruction: normal finding • Partial or delayed relaxation • No: Absent = nonrelaxing PFM (see 2.1.8.1)
2.2.17 Co-ordination: The ability to use different parts of the body together smoothly and efficiently.[24] In the pelvic floor, co-ordination may be an action between PFMs and organ function (e.g., PFM relaxation during voiding), PFMs and an external environmental event (e.g., movement of a limb) and PFMs and a rise in IAP (e.g., PFM contraction before a cough). Co-ordination is an aspect of motor control.	• Present • Absent. If absent, describe pattern of incoordination. e.g., paradoxical contraction: the inability to maintain PFM relaxation when it is expected; or lack of PFM contraction when it is expected
2.2.17.1 Co-contraction: Contraction of two or more muscles at the same time.[24] Co-contraction of muscles can be synergistic (e.g., resulting in an augmentation of motor activity) or it could be counterproductive to normal function (e.g., contraction of antagonistic muscles resulting in abnormal movement or training other muscles instead of the targeted ones, e.g., training of gluteal muscles instead of the PFM).[24] Activation or inhibition of PFM contraction may be task-dependent	• If present, identify which muscles are co-contracting, and whether the co-contraction is synergistic or counter-productive[e]

Abbreviations: DMT, digital muscle test; EAS, external anal sphincter; *f*, female; IAP, intra-abdominal pressure; *m*, male; MVC, maximum voluntary contraction; PFM, pelvic floor muscles; *PR*, *per rectum*; *PV*, *per vaginam*.

[a]This term is referring to a sign and not recommended to be used as a diagnosis. This sign may be combined with symptoms to inform a clinical diagnosis.

[b]Endurance training can delay the onset of fatigue.[70]

[c]Modification from Bo et al.[24]: removal of "at a given percentage of 1 RM" as definition already states "near maximal or maximal force."

[d]This can only be graded if the patient is able to generate a PFM contraction.

[e]Antagonistic contraction has not been included in this document as there is not a muscle whose action counteracts the action of the PFM.

is the term "wind," which is defined below. In addition to documenting the patient's symptom (term) and any other descriptors the patient uses to describe the symptom, the assessor documents the perceived location, frequency of occurrence, severity, distress, bother or impact of these symptoms to the patient.

1.1 PFM sensory symptoms: Patient terms may include numbness, reduced feeling, decreased sensation, tingling, pins and needles, sensitivity/hypersensitivity, or increased or unusual sensation in the region the patient perceives to be related to the PFM. Terms used to describe painful symptoms may include pain, tender, ache, burning, or discomfort in the region the patient perceives to be related to the PFM; use of existing descriptors in published scales[10] is recommended.

1.2 PFM motor symptoms*:* Patient terms may include loose, lax, gaping, sagging, open, weak, bulging, heaviness, full, loss of control, or difficulty to relax, tight, tense, narrow, or constricted. A patient may describe "wind" as a noise or passage of gas.

1.2.1 Vaginal wind: An involuntary passage of odorless air through the vagina, which is often audible and/or sensible, and usually associated with a change in posture **(CHANGED)**.[11,12,ii] This may occur when legs are abducted and a change of position occurs and during times of low estrogen (e.g., breast-feeding).

1.2.2 Anal wind[iii]: Complaint of involuntary loss of flatus (gas). **(NEW)**

Following the assessment of a patient's symptom(s), the assessor will formulate provisional differential

TABLE 7 Tests of digital palpation *per vaginam* only *(f)*, on PFM contraction[a]

Test	Rating
2.2.19 Urethral lift: Elevation of the urethra in a cephalad direction.[15] **(NEW)** Index finger is placed along the line of the urethra (on the anterior vaginal wall)	• Yes: Urethral lift palpable • No: No urethral lift palpable
2.2.20 Levator closure: Movement of right and left muscle bellies closer together during a PFM contraction (palpated on the lateral vaginal wall).[15] **(NEW)** May be tested unilaterally if bi-digital assessment is uncomfortable for the patient	• Yes: Levator closure movement palpable • Partial/uncertain: Some closure movement palpable, but could be un-certain, or asymmetrical • No: No levator closure movement palpable
2.2.21 Levator hiatus size: The size of the levator hiatus measured during maximal contraction by a digital examination[71b] **(NEW)**	• With 2 fingers in the vagina, distance measured in centimeters (converted approximately from finger widths) during PFM contraction • LH transverse: The distance between the left and right muscle bellies just inferior to the pubic bone • LH sagittal: The distance between the back of the pubic symphysis and the midline raphe of the puborectalis[71]

Abbreviations: LH, levator hiatus; *PV*, *per vaginam*.

[a]These tests are likely to produce more accurate results if measured using ultrasound imaging.

[b]This test was performed in patients with POP; the same technique may be uncomfortable in women with pelvic floor pain or increased tone.

diagnoses which will be refined following the clinical examination.

3 | SECTION 2: SIGNS

Signs are elicited from the clinical examination, which includes visual observation, physical inspection, and simple tests.[iv] The majority of PFM clinical signs are tested using digital palpation. The term "palpation" (latin origin: *palpare*) means to touch gently or to use the fingers or hands to examine.[14] Palpation allows the assessor to feel the texture, size, consistency, and location of certain body parts with the hands, or in the case of PFM assessment, with the fingers or finger-tips.[v] Due to the inherent subjective nature of visual and digital assessment, many of these characteristics and properties of the PFM are more accurately assessed using investigations. While some terms will be defined in signs, the measurement of that term may be better done in investigations. If an assessor does not have access to investigations, findings from signs may be used to guide practice, however, subsequent research may cast doubt on the certainty of findings from signs.

There are several aspects for the assessor to be aware of during the clinical assessment which apply to all measured aspects of PFM function, as variations in the examination conditions or maneuvers may alter the results of the test and reduce the certainty of the finding. These are listed in Box 1. We recommend all of these aspects should be reported by assessors to enable reproducibility of assessment. Akin to published checklists for exercise prescription,[17] checklists of clinical assessment may improve completeness and quality of research reports.

This section divides the clinical examination into an external PP assessment and an internal *PV* or *PR* assessment. The order of examination for PP assessment is visual observation before digital palpation. The full description of each term appears in the subsequent tables and text. Not all tests may be applicable for each patient; the decision to perform a test should be based upon clinical judgment.

2.1 External assessment per perineum

Visual observation: All terms related to the visual observation per perineum under different PFM states (at rest, on contraction, and with raised intra-abdominal pressure [IAP]) are listed and defined in Table 2.

Digital palpation: All terms related to digital palpation *per perineum* under different PFM states (at rest, on contraction, and with raised IAP) are listed and defined in Table 3.

2.2 Internal assessment *per vaginam* (PV) or per rectum (PR) by digital palpation

Resting state: The following terms (in Tables 4 and 5) are used to define, describe and rate PFM assessment in the resting state *per vaginam* (*PV*) or *per rectum* (*PR*) by digital palpation. Terms related to muscle tone are expanded upon in subsequent text to provide greater explanation of the term definitions and descriptions.

2.2.3 Muscle tone

Tone exists on a continuum, from hypotonicity (low tone) to hypertonicity (high tone). Normal tone may

TABLE 8 Parameters and findings evaluated with intravaginal dynamometry

Parameters, specifications (units of measure) and measurement processes	Outputs and interpretation of findings
(a) Parameters assessed at rest	
3.1.1 Passive forces: The average forces in N recorded at rest[84] **(NEW)** Specify: – Opening (distance between the two branches e.g., minimal opening, selected opening or maximal opening) – While stretching (dynamic opening)	The finding is the resting forces of the PFMs which are indicative of PFM tone, i.e., the summative contribution of the active and passive components of tone
3.1.2 Maximal aperture: The maximal vaginal opening in mm or cm of the dynamometer branches, without provoking a pain response[86] **(NEW)**	This aperture can be used to evaluate the flexibility[a] of the PFMs
3.1.3 Viscoelastic stress relaxation during a static (sustained) stretch: The percentage loss in passive force during the application of a steady stretch over a prolonged period (e.g., 1 min)[85,88] **(NEW)**	Higher percentage of force decline is indicative of an enhanced viscoelastic stress relaxation response and muscle relaxation. This could be useful in quantifying tissue relaxation following stretching or lower force decline associated with strength training[88]
(b) Parameters assessed at rest during dynamic stretching	
Dynamic stretches are applied by repeatedly separating the speculum branches at a constant speed until maximal vaginal aperture (lengthening phase) and then, closing back to the minimal aperture (shortening phase)	
3.1.4 Stiffness: The resistance to deformation. Passive elastic stiffness is defined as the ratio of the change in the passive resistance or passive force (ΔF) to the change in the length displacement (ΔL) or $\Delta F/\Delta L$ (N/mm)[24,43,75b]. Passive elastic stiffness should be computed for specific vaginal apertures[81,84]	The higher the N/mm value, the stiffer the muscle. This is a physiological property of muscle which contributes to the overall measurement of tone
3.1.5 Compliance: the reciprocal of muscle stiffness (mm/N)[43] **(NEW)**	The higher the mm/N, the more compliant the tissue
3.1.6 Hysteresis: The area between the lengthening and shortening curves (N × mm). It corresponds to the loss of energy associated with lengthening of viscoelastic tissues[85] **(NEW)**	Increased area indicates higher energy dissipated
(c) Parameters evaluating contractile properties	
3.1.7 Maximal strength: Peak force in N generated during a MVC. **(NEW).** The resting forces recorded before the effort are usually subtracted from the peak value[78]	Higher peak value indicates higher muscle strength
Specify: – The length of hold for the MVC, e.g., 10 s contraction duration – How the peak score was obtained, e.g., peak during a single MVC, best of or average of 3 contractions	
3.1.8 Speed of contraction: Rate of force development measured as the mean slope of the ascending curve in N/s during a fast MVC[79] **(NEW)**	Higher rate of force (steeper slope) is indicative of a faster generation of force
3.1.9 Speed of relaxation: Rate of force reduction measured as the mean slope of the descending curve in N/s during PFM relaxation[86] **(NEW)**	Lower values are indicative of slower relaxation
3.1.10 Number of rapid contractions: See section 2.2.16 for definition and rating. A contraction must comprise an ascending and a descending phase with the amplitude of the PFM forces returning to the resting state post contraction[79]	Higher number of contractions are suggestive of higher speed of contraction but also better motor control, as the task requires alternation between MVC and complete rest

TABLE 8 (Continued)

Parameters, specifications (units of measure) and measurement processes	Outputs and interpretation of findings
3.1.11 Normalized area under the force curve: The area under the force curve divided by maximal force and multiplied by 100 (in % × prescribed s) during a sustained MVC[79] **(NEW)**	Higher normalized area is indicative of better muscle endurance

Abbreviations: MVC, maximum voluntary contraction; N, Newtons; PFM, pelvic floor muscles.

[a]See section 2.2.9 for definition.

[b]Using the dynamometer alone, the stiffness value will reflect the summative contribution of the active and passive components of tone. If dynamometry is combined with EMG, the passive contribution can be identified.[86]

overlap with abnormally decreased muscle tone or abnormally increased muscle tone at either end of the tone spectrum, as illustrated in Figure 2. Tone is a dynamic physiological state modulated by many inputs: spinal cord, cortex, brainstem relays, stretch reflexes and cutaneous receptors, visceromotor reflex pathways, emotions, and pain (anticipation or experience of pain).

We recommend terms to indicate alterations to normal tone are differentiated according to the presence or absence of a neurological disorder, as illustrated in Figure 3. Abnormal tone related to a neurological disorder (hypotonicity, hypertonicity, dystonia) should not be used when describing PFM tone in a patient who does not have a diagnosed neurological disorder.

Physiological basis of muscle tone

Muscle tone has two components: the physiological contractile component, created by the activation of motor units, and the noncontractile viscoelastic, or biomechanical component. The active component (EMG activity) of tone is the component that is related

TABLE 9 Parameters and findings evaluated with myotonometry

Parameters, specifications (units of measure) and measurement processes	Outputs and interpretation of findings
3.2.1 Oscillation frequency: Characterizes the intrinsic tension of the muscle in its passive or resting state in the absence of voluntary contraction.[93] **(NEW)** Measured in Hz	A higher oscillation frequency (Hz value) indicates higher muscle tone[92,93]
(a). Biomechanical properties	
3.2.2 Stiffness: As defined in 3.1.4 for dynamometry. However, the method of application of the force is different to that described in 3.2.2; with this device, an external sensor applies a deformation perpendicular to the tissue	A higher N/m value indicates higher muscle stiffness.
3.2.3 Logarithmic decrement: Characterizes elasticity and dissipation of mechanical energy. Measured as $1n$ ($D = \ln [a1/a3]$).[93] It indicates the ability of the tissue (including muscle) to recover its shape after being deformed **(NEW)**	Elasticity is inversely proportional to decrement, therefore, if the decrement of a muscle decreases, the muscle elasticity increases. The smaller the decrement value, the smaller will be the dissipation of mechanical energy and the higher the elasticity of a tissue
(b) Viscoelastic properties	
3.2.4 Mechanical stress relaxation time: The time for a muscle to recover its shape from deformation after a voluntary contraction or removal of an external force **(NEW).** Measured in milliseconds[92]	The longer the time the more relaxation has occurred in the tissue
3.2.5 Creep: The gradual elongation of a tissue over time when placed under a constant tensile stress. **(NEW)**: Measured by the the ratio of relaxation time to deformation time (Deborah number)	The higher the creep, the less elasticity the tissue has and the more likely is permanent stretch or deformation

Abbreviations: Hz, hertz; N/m, newtons/meter.

TABLE 10 Parameters and findings evaluated with pelvic floor manometry

Parameters, specifications (units of measure) and measurement processes	Outputs and interpretation of findings
(a) Parameters assessed at rest	
3.3.1.1 Resting pressure: The pressure recorded at rest in mmHg, hPa or cmH_2O. For greater accuracy, a mean resting pressure may be calculated over a specified period to account for fluctuations[95,96] (**NEW)** Resting pressure may be influenced by PFM tone (i.e., summative contribution of the active and passive components)	Higher resting pressure may be a surrogate measure of increased PFM tone. However, the value should be interpreted with caution as the measurement is not limited to pressure originating from the PFMs (e.g., intra-abdominal pressure, vaginal tissue scaring, rectal contents may contribute to resting pressure)
(b) Parameters evaluating contractile properties	
3.3.1.2 Peak pressure during a maximum voluntary contraction: highest pressure recorded during a PFM MVC in mmHg, hPa or cmH_2O (**NEW)** As the pressure measured does not confirm its origin, it is important to ensure the validity of intra-vaginal measurement: (1) perform vaginal palpation before using the manometer to ensure the patient is able to correctly contract her PFMs; (2) observe the cranial movement of the vaginal probe during measurement of the muscle contraction, and (3) ignore contractions associated with elevated intra-abdominal pressure (e.g., Valsalva maneuver), hip muscle contraction or any movement of the pelvis[97,98a]	Maximal pressure is often used as a surrogate of muscle strength, e.g., higher pressure being related to higher strength
Specify: – The length of hold for the MVC, e.g., 3 s/5 s/10 s contraction duration – How the peak score was obtained, e.g., peak during a single MVC/best of or average of 3 contractions[99–106]	
3.3.1.3 Time to peak pressure: Time in seconds from onset of muscle contraction to maximal pressure (**NEW)**	Shorter time to peak is indicative of a faster generation of pressure
3.3.1.4 Speed of contraction: Rate of pressure rise measured as the mean slope of the ascending curve in hPa/s during a fast MVC (**NEW)**	Higher rate of force (steeper slope) is indicative of a faster generation of pressure
3.3.1.5 Speed of relaxation: Rate of pressure reduction measured as the mean slope of the descending curve in hPa/s during PFM relaxation (**NEW)**	Lower values are indicative of a slower relaxation
3.3.1.6 Number of rapid contractions: See 2.2.16 and 3.1.10 for definitions and ratings	See 3.1.10 for interpretation
3.3.1.7 Time to return to baseline pressure: Time in seconds from maximal pressure to relaxation state (**NEW)**	Longer duration suggests slower relaxation
3.3.1.8 Duration of a sustained contraction: The length of time in seconds that a contraction can be sustained during MVC or at a specific % of MVC. (**NEW).**Specify if it is a maximal contraction or a % of MVC, e.g., 60%[96,99,101,102,105] and the threshold used to indicate that the target is no longer maintained	A shorter duration suggests a lower endurance. Duration of contraction could be used as an indication of endurance, e.g., longer contraction being related to better endurance
3.3.1.9 Area under the pressure curve during a sustained contraction: The area under the pressure curve in hPa multiplied by time in s during a sustained MVC or at a specific percentage of MVC. This represents the total work performed. (**NEW).** Specify the duration of the contraction, e.g., 10 s, 30 s, etc.[95,100]	Higher area under the pressure curve above resting pressure reflects better muscle endurance

Abbreviations: MVC, maximum voluntary contraction; PFM, pelvic floor muscles.

[a]It is not recommended to use intravaginal pressure manometry to assess the reflex contraction of the PFM during coughing.[107] Bo and Constantinou[107] explained that pressure measurement is a summation of signals including PFM and intra-abdominal pressure caused by the cough itself and therefore, it is unlikely that the PFM reflex can be assessed in isolation using pressure manometry. In contrast, ano-rectal manometry can be used to assess a reflex during an involuntary PFM contraction[108] if the transducer is located in the anus, caudal to the puborectalis/ano-rectal junction; therefore it is not impacted directly by intra-abdominal pressure.

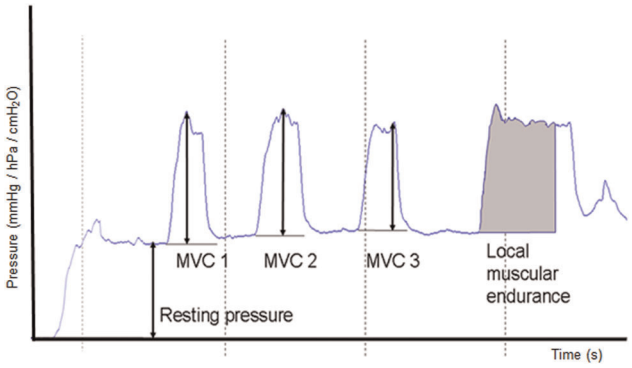

FIGURE 4 Graphical illustration of pelvic floor muscle manometry readings (modified from Ingeborg H Braekken, with permission)

to the neural drive, therefore it is subject to variation and ongoing adjustment. The viscoelastic component is independent of neural activity and reflects the passive physical properties of the viscoelastic tension of the muscle tissues (e.g., the extensibility of actin-myosin cross-bridges); noncontractile cytoskeleton proteins and connective tissues surrounding the entire muscle (epimysium), muscle fascicle (perimysium), and muscle fiber (endomysium) as well as the osmotic pressure of the cells. Alterations in either the active or passive component can affect the resting tone; digital palpation cannot differentiate between these elements however investigations that combine EMG with another measure that assesses passive properties can identify specific components.

A localized area of increased tone within a muscle may be referred to as a taut band.[51] A trigger point is considered to be a tender nodule within a taut band.[51] The trigger point is considered by some authors to be part of the active component of tone[51] given the local disturbance in electrical activity, and by others as a separate category distinct from the active or passive components of tone.[52] Given the uncertainty about the characterization of a trigger point,[53,54] we propose describing palpatory findings by use of the terms "tender point" (2.1.15.1) and "increased tone" (2.2.3.4) if both observations coincide at the tested site, or use only "tender point" (2.1.15.1) or "increased tone" (2.2.3.4) if only one of those signs is observed at the tested site.

Assessment and rating

Tone can be assessed by application of digital site-specific compression and/or overall muscle stretch. Digital palpation is inherently subjective and may be limited by pain provocation.

Several scales to quantify resting PFM tone in the absence of a neurological disorder have been proposed using either a 3-point,[55,56] 6-point,[48] or 7-point[57] scale.

Definitions and descriptions

2.2.3.1 Hypotonicity: A decrease in muscle tone in a patient **with** a neurological disorder. It may be due to a lower motor neuron or a muscle disorder. The term flaccidity[58] is often used interchangeably. (**NEW**)

2.2.3.2 Hypertonicity: An increase in muscle tone in a patient **with** a neurological disorder. It may be due to an upper motor neuron or extrapyramidal lesion, which in turn may lead to spasticity[58] or rigidity.[58] (**NEW)**

2.2.3.3 Dystonia: A disorder characterized by abnormalities of muscle tone and movements/postures in a patient **with** a neurological disorder.[59] It is often due to damage to the basal ganglia or other brain regions that control movement. **(NEW)**

2.2.3.4 Decreased PFM tone: A decrease in resting muscle tone in a patient **without** a neurological condition **(CHANGED)**[43]

2.2.3.5 Increased PFM tone: An increase in muscle resting tone in a patient **without** a neurological disorder. **(CHANGED)**.[43] Increased tone may occur without patient report of pain.

2.2.3.5.1 Transient increased muscle tone: Increased muscle tone that decreases with verbal instruction, re-assurance, or gentle pressure **(NEW).** Transient increase in tone may occur at any time during the examination.

2.2.3.5.2 Muscle spasm: Persistent contraction of muscle that cannot be reduced voluntarily.[11,24,43] Spasms may occur at irregular intervals with variable frequency and extent, and over time may lead to increased viscoelastic stiffness and shortening in the muscular and connective tissues.[vii,viii]

Resting state *per vaginam* (*PV*) only (*f*)*:*** Terms related to digital palpation of the vaginal tissues with the PFMs in a resting state are listed in Table 5.

PFM contraction: The following terms in Table 6 are used in the definition and the ratings of digital assessment *per vaginam*/*per rectum* of the PFMs during contraction.

PFM contraction per vaginam (*PV*) only (*f*): Terms related to digital palpation *per vaginam* only (*f*), on PFM contraction are listed in Table 7.

PFM response to intra-abdominal pressure *per vagina* morper rectum

2.2.22 Direction of PFM movement during sustained increase in IAP: As per 2.1.9. Specify task instruction, as response may differ depending on wording. Rate as elevation, no change, descent (normal finding), excessive descent.

TABLE 11 Parameters and findings evaluated with anorectal manometry

Parameters, specifications (units of measure) and measurement processes	Outputs and interpretation of findings
(a) Parameters assessed at rest	
3.3.2.1 Functional anal length: The length (mm) of the anal canal over which resting pressure exceeds that of the rectum. **(CHANGED)**[11] The length of the canal is measured either by station pull-through or continuous pull-through[11]	Functional anal canal length has been shown to be shorter in females with fecal incontinence and longer in females with chronic constipation[109]
3.3.2.2 Maximum resting pressure: The highest pressure (in mmHg, hPa, or cmH_2O) along the anal canal measured in the axial plane at a specific point **(CHANGED)**[11]	Internal anal sphincter (IAS) (smooth muscle) is responsible for 55%–85% of the anal pressure, and is variable along the length of the anal canal with the proximal two-thirds being more reliant on IAS tone to maintain adequate resting pressures. Low anal resting pressure is associated with passive fecal soiling. High anal resting pressure may be a feature of constipation[110]
(b) Parameters evaluating contractile properties	
3.3.2.3 Maximum pressure during MVC/maximum squeeze pressure: Is the anal canal pressure (in mmHg, hPa or cmH_2O) measured during maximum voluntary contraction (MVC) in a specific location **(CHANGED)**[11]	The pressure increment above resting pressure during these maneuvers is primarily a representation of EAS function. Range of normative values varies according to the particular measurement device in a laboratory.[11] Decreased voluntary anal sphincter contraction is associated with fecal incontinence especially fecal urgency[110]
3.3.2.4 Duration of sustained contraction MVC/endurance squeeze pressure: Is the length of time (in seconds) the individual is able to maintain the pressure during the MVC **(CHANGED)**[11]	Shorter duration suggests a lower endurance. To assess the endurance squeeze pressure, measurements are taken during a 5–10 s squeeze. By calculating fatigability, the fatigue rate (using reduction of the mean pressure over 1-s periods throughout the endurance squeeze) can be derived[11]
3.3.2.5 Number of rapid contractions: See 2.2.16 and 3.1.10 for definitions and ratings	See 3.1.10 for interpretation.
3.3.2.6 Involuntary maximum squeeze pressure: The pressure (in mmHg, hPa, or cmH_2O) created involuntarily by the PFM during a maximal cough[108] **(CHANGED)**[11a]	• Present; numerical values of pressure change may be used to further quantify • Absent; associated with fecal incontinence[111]
3.3.2.7 Balloon expulsion pressure: The anal canal pressure (in mmHg, hPa, or cmH_2O) during straining with a filled balloon in the rectum[11]	• Increase from resting pressure suggests paradoxical contraction (see 4.3.1) and is associated with evacuation dysfunctions • No change • Decrease from resting pressure (normal)
3.3.2.8 Rectoanal inhibitory reflex (RAIR): The relaxation response in the IAS following rectal distension (in mmHg, hPa, or cmH_2O).[11] It is elicited by rapid inflation to first sensation of a balloon positioned in the distal rectum during anal manometry at the level of the proximal high-pressure zone	• Present: a drop of at least 25% of resting pressure has to occur with subsequent restoration to at least two-thirds of resting pressure for the RAIR to be deemed present. This reflex is thought to underlie the sampling response that allows rectal contents to be sensed by the anal mucosa, thus ensuring continence of flatus and stool[11,112] • Absent: seen in Hirschsprung disease, fecal incontinence, constipation, and after anorectal surgery[110]

Abbreviations: IAS internal anal sphincter; MVC, maximum voluntary contraction; PFM, pelvic floor muscles.

[a]This contrast with vaginal manometry where the source of pressure during an involuntary contraction cannot be assumed to be the levator ani contraction.

Box 2 EMG system specifications

Recommendations for reporting EMG studies (based on the recommendations of the International Society of Electrophysiology and Kinesiology[113]).

Reports on surface EMG should include:

- electrode material (e.g., Ag/AgCl)
- electrode geometry (discs, bars, rectangular)
- number and size (e.g., diameter, radius, width, length)
- interelectrode distance
- use of gel or paste
- skin/mucosal preparation (e.g., alcohol applied to cleanse skin, skin abrasion, shaving of hair, etc.)
- electrode location, orientation over muscle with respect to tendons, motor point (if known) and muscle fiber direction.
- type of ground electrode used, location

Reports on intramuscular wire electrodes should include:

- wire material (e.g., stainless steel)
- if single- or multistrand
- if single or bipolar wire
- interelectrode distance
- insulation material
- length of exposed tip
- method of insertion (e.g., hypodermic needle)
- depth of insertion/method of insertion guidance
- location of insertion in the muscle
- type of ground electrode used, location

Amplifiers should be described by the following:

- type (monopolar, differential, double differential, etc.)
- pre-amplification at the level of the electrode
- input impedance
- Common Mode Rejection Ratio (CMRR)
- actual gain range used

Filtering of the raw EMG should be specified by[XII]:

- low and/or high pass filter properties (e.g., cut-off frequencies, order)
- filter types (e.g., Butterworth, Chebyshev, Notch, etc.)
- notch filter

Following the assessment of a patient's clinical signs, the assessor will formulate a provisional differential diagnosis which will be refined following the results of the investigations.

4 | SECTION 3: INVESTIGATIONS

An investigation is part of the differential diagnostic decision-making process. A PFM investigation is the measurement of the morphometry or function of the PFMs using mechanical or technological methods. The findings may be considered more accurate than findings from a clinical evaluation which relies on digital palpation. Some points to note regarding PFM investigations that should be considered in clinical and research application and interpretation of the finding: all devices are different and may not give the same information of a specific PFM physiological parameter or function. In addition, device specifications and analysis software options influence both the availability and measurement of PFM parameters,[72,73] the size and shape of a probe/sensor/electrode/transducer also influence the interpretation of findings[72–74] and raw values may need to be normalized. New devices to measure PFM properties may become available in the near future which do not fit the existing categories entirely, and new categories may need to be added to this living document.

3.1 ***Dynamometry***: An investigation that measures both muscle power and force **(CHANGED)**. Both active (contractile) and passive (noncontractile) forces can be detected.

3.1.a Intra-vaginal PFM dynamometry: Measurement of PFM resting and contractile forces using strain gauges mounted on a speculum (a dynamometer), which is inserted into the vagina[75] **(CHANGED)**.

Several PFM dynamometers have been developed to assess the PFM function in women.[76–84] Different configurations have been proposed in terms of the number, shape and the sizes of the branches, the force vector recorded (i.e., antero-posterior, latero-lateral or multidirectional forces) and the device specifications (e.g., configuration of strain gauges to avoid a lever-arm effect—the influence of the force location in regard to the gauges). In some dynamometers, the branches can be separated at a constant speed either manually or with a motorized unit to assess the passive properties during dynamic stretches.[81,85] Elastometry is a type of intra-vaginal PFM dynamometer used for this specific application of evaluating the passive properties during dynamic stretches.[81]

Table 8 describes the most frequent parameters measured with intra-vaginal dynamometers as well as their definitions, specifications and findings. Parameters can be assessed at different fixed vaginal apertures or during stretching (i.e., while imposing an elongation to the tissues by separating the speculum branches).[81,84] The parameters measured with the dynamometer alone

TABLE 12 Parameters and findings evaluated with sEMG

Parameters, specifications (units of measure) and measurement processes	Outputs and interpretation of findings
(a) Parameters assessed at rest	
3.4.2.1 Baseline muscle activity: The amount of microvolts generated by activation of motor units in the target muscle during rest[24,75a,b]	**3.4.2.1.1 Inconsistent resting baseline**: The variation of baseline between contractions, between sets, or between days[24,75] **3.4.2.1.2 Elevated resting activity**: An increase in the active component of muscle tone; (the passive/viscoelastic component is not captured by sEMG) (**NEW**)
(b) Parameters evaluating contractile properties	
3.4.2.2 Signal amplitude: Microvolts (μV) a muscle generates[24] Specify: MVC contraction duration (s)—how the signal was processed. Signals are usually rectified and filtered to measure amplitude,[114] i.e., average rectified value or root-mean-square[114] **3.4.2.3 Peak amplitude**: The highest sEMG amplitude achieved measured in microvolts.[24,75] Specify the duration (s). Measured during an MVC or functional activities such as postural tasks or incontinence provocative activities[123,124c] **3.4.2.4 Normalization of the amplitude**: The value obtained during a specific task as a percent relative to the electrical activity detected during a MVC[113,117] (**NEW**)	sEMG amplitude reflects muscle activation.[117] Increase in sEMG amplitude is related to the recruitment of motor units and increased firing rate.[118] The amplitude of the signal should not be interpreted as a direct force measurement because the relationship between force and EMG is generally not linear and is affected by type of contraction (concentric/isometric/eccentric), speed of contraction.). During strength training, early gains in force output are mainly related to an increase in motor unit recruitment and discharge frequency which will result in a higher signal amplitude. Later gains explained by hypertrophy[24] are not reflected in increased sEMG amplitude
3.4.2.5 Time to peak muscle activation: Time in ms or s from onset of muscle activity to peak activity (**NEW**) **Rate of change**: The mean slope of the ascending curve in μVs during a fast MVC. (**NEW**)	**3.4.2.5.1 Slow recruitment**: A longer time to peak muscle activation in s or a slower rate of change[125] **(CHANGED)**[24d,e]
3.4.2.6 Reaction time: The latency (time in ms) between a stimulus (or the command) and the onset of muscle activation[126] (**NEW**)[f] **3.4.2.7 Time from command to peak**: Time in ms from stimulus to peak activity (**NEW**) This term encompasses both the reaction time and the time to peak muscle activation	**3.4.2.6.1 Slow reaction time**: A longer time to initiate muscle activation (**NEW**)
3.4.2.8 Time to return to baseline muscle activity: Time in s from peak activity to resting activity (**NEW**) **Rate of change**: The mean slope of the descending curve in uV/s during a fast MVC	**3.4.2.8.1 Slow de-recruitment**: Slow relaxation of the muscle contraction[24]
3.4.2.9 Rate of change of amplitude during sustained contraction: The change in sEMG amplitude divided by the duration of the contraction: $EMG_{final} - EMG_{initial}$/time(s).[127] (**NEW**). The contraction could be sustained or intermittent at different % of MVC[127]	A higher rate of change will be indicative of lower endurance
3.4.2.10 Timing of muscle activity: Onset of the activation in milliseconds can be assessed in relation to onset of activation in other muscles, provocative activities or other aspects of a task (**NEW**)	• Normal • Delayed: delayed activation of the PFM relative to the onset of a cough or a postural perturbation has been found in women with stress urinary incontinence[124]

TABLE 12 (Continued)

Parameters, specifications (units of measure) and measurement processes	Outputs and interpretation of findings
3.4.2.11 Duration of a sustained contraction: The duration in seconds that a contraction could be sustained at a specific % of MVC[127] **(NEW)**	A shorter duration suggests lower endurance
3.4.2.12 Power spectrum: The distribution of frequency components of the sEMG signals, measured in Hz[114] **(NEW)**	The median frequency of the sEMG power spectrum shifts to lower frequencies as a muscle fatigues due to altered muscle fiber recruitment and other changes in the contractile properties[128,129]

Abbreviations: MVC, maximum voluntary contraction; PFM, pelvic floor muscles; sEMG, surface electromyography; uV microvolts.

[a]The recording of resting activity is highly susceptible to contamination by ambient noise. A low proportion of noise in the signal (or higher signal-to-noise ratio) is necessary for accurate assessment.

[b]Unlike many other skeletal muscles,[130,131] the PFMs are thought to have a level of constant EMG activity to maintain continence and support of pelvic/abdominal contents.

[c]Advanced EMG techniques are needed to prevent inaccurate interpretation from artifacts and muscle crosstalk.

[d]Slow recruitment could be a sign of PFM dysfunction if it leads to leakage during coughing and sneezing when a quick muscle contraction is needed to counteract increased intra-abdominal pressure.[24,75]

[e]The definition for this term used in Bo et al.[24] is the definition this document calls "slow reaction time."

[f]This may also be considered in the motor control domain.

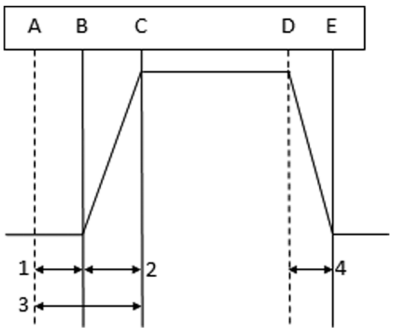

FIGURE 5 Parameters measured using electromyography. Parts of the EMG tracing: A = signal to contract, B = onset of muscle activity, C = peak muscle recruitment, D = signal to relax, E = return to baseline; 1 = Reaction time, 2 = Time to peak activation, 3 = Time from command to peak, 4 = Time to return to baseline muscle activity

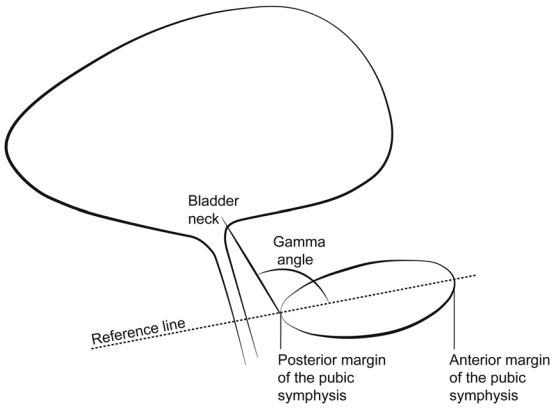

FIGURE 7 Perineal ultrasound parameter (gamma angle) assessed in the mid-sagittal plane using a reference line drawn from the anterior to the posterior margin of the pubic symphysis

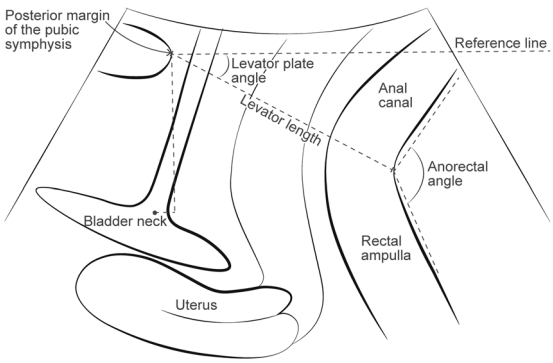

FIGURE 6 Perineal ultrasound parameters and anatomical landmarks assessed in the mid-sagittal plane using a horizontal reference line drawn from infero-posterior margin of the pubic symphysis

reflect the summative contribution of the active and passive components of tone. When combined with EMG, it enables the assessment of the differential contributions of tone components,[86] that is, during passive stretch of the PFM, concurrent EMG activity detects any electrogenic contributions. The passive component can then be identified when the EMG remains negligible.[86,87]

3.2 Myotonometry: An investigation that measures muscle tone characteristics by applying a mechanical impulse to the tissue.[89–91] **(NEW)** The device elicits oscillations of muscle after a probe applies a brief mechanical impulse with quick release under constant preload to the skin over the muscle belly. Myotonometry has been used externally on the perineum to measure superficial PFM stiffness. It cannot be used intravaginally to measure levator ani function as the probe

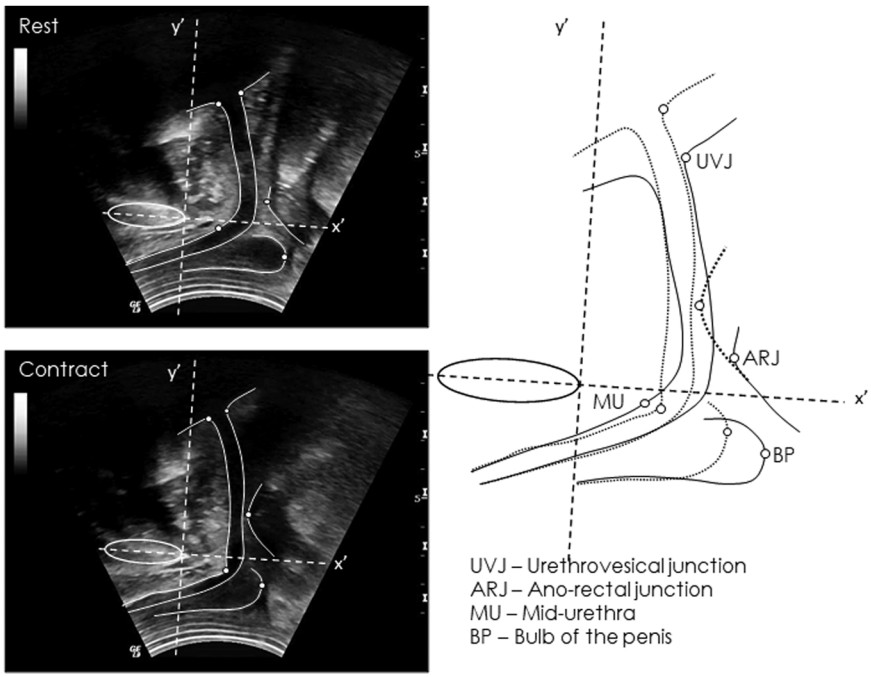

FIGURE 8 Parameters and anatomical landmarks assessed in the mid-sagittal plane using a two-dimensional transducer oriented longitudinally/sagittally in men (reproduced with permission from Stafford et al.[132]). The sketch overlays two images illustrating the anatomy at rest (continuous lines) and during maximal pelvic floor contraction (dotted-lines)

must be perpendicular to the muscle and therefore cannot be used to interpret levator ani function. Table 9 describes the most frequent parameters measured with myotonometry that can be computed from the oscillation curve as well as their definitions, specifications and findings.[92] It should be noted that the tissues that lie between the probe and the muscle (e.g., skin, adipose tissues, connective and fascial tissues) can also influence the measurements.

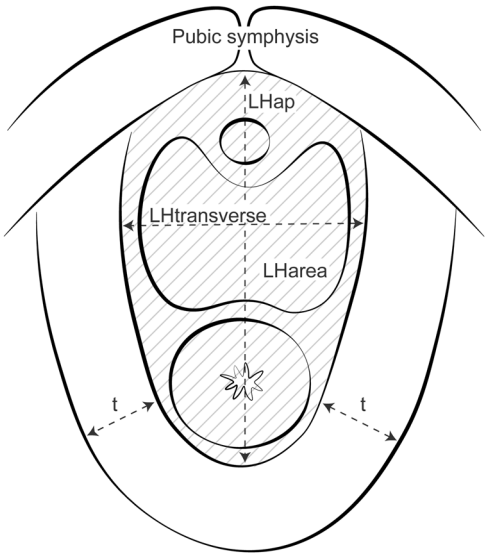

FIGURE 9 Levator hiatal dimensions measured using perineal ultrasound. LHap, levator hiatus antero-posterior diameter; LHarea, levator hiatus area; LHtransverse, levator hiatus transverse diameter; t, pubovisceral thickness

3.3 Manometry: An investigation that measures pressure[24,75]

3.3.1 Pelvic floor manometry: Measurement of resting pressure or pressure rise generated during contraction of the PFM using a manometer connected to a sensor, which is inserted into the urethra, vagina or rectum.[24]

3.3.1.a) Intra-urethral manometry: Manometry performed via the urethra. One example is the urethral pressure profile that is undertaken as part of a urodynamic investigation.[94] (**NEW**)

3.3.1.b) Intra-vaginal manometry: Manometry performed via the vaginal canal. (**NEW**)

3.3.1.c) Intra-anal manometry[ix]: Manometry performed via the anal canal. (**NEW**)

Pelvic floor manometric tools traditionally have measured pressure in mmHg, hPa, or cmH_2O, however, new and future devices may provide output using different units. It should be specified whether the device is calibrated to zero/atmospheric pressure before insertion.[24] The most common parameters assessed with pelvic floor manometry (intra-vaginal and intra-anal) and their findings are described in Table 10. Several common parameters are illustrated in Figure 4.

3.3.2 Anorectal manometry[x]: Is a pressure test to assess the structure and physiological function of the anorectal complex **(CHANGED)**.[11] Water perfused and solid-state pressure transducers are used in combination with a balloon positioned in the anal canal.[23] The most commonly used PFM parameters and findings are described in Table 11.[xi]

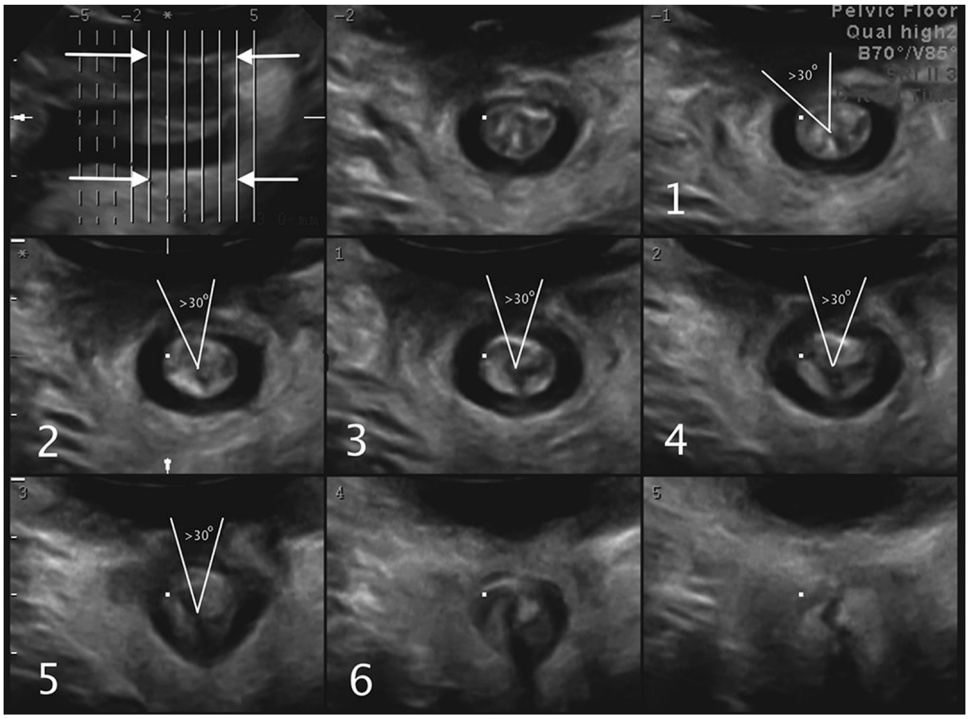

FIGURE 10 Assessment of the integrity of the anal sphincter complex assessed with tomographic ultrasound imaging plane (reproduced with permission from Guzman Rojas et al.[133])

3.3.2.9 Vector manometry: A three-dimensional pressure profile of the anal canal. **(CHANGED)**.[11] Measures of total anal canal pressure and symmetry are made. The vector volume is the volume of the 3D shape generated and provides a value which reflects the overall length and symmetry of the sphincter.

3.3.2.10 High resolution manometry: Complete definition of the intra-anal pressure environment using a catheter with a large number of pressure sensors spaced less than 0.5 mm apart along the length of the catheter.[11]

3.3.2.11 Ambulatory anorectal manometry: Is a test performed using solid-state catheters in ambulant

TABLE 13 Parameters and findings evaluated with trans-abdominal ultrasound imaging in the mid-sagittal plane

Parameters, specifications (units of measure) and measurement processes	Outputs and interpretation of findings
3.5.1.1.1 Bladder base displacement[a]: A marker is placed at the point of greatest displacement (mm or cm) of the infero-posterior bladder wall at rest and at maximal contraction or bearing down.[137] Direction and displacement of the bladder base movement from rest to final position. **(NEW).** The bladder base is the most infero-posterior aspect of the bladder wall	*PFM contraction:* Displacement from rest of the bladder base during (attempted) PFM contraction[138]: • Elevation (normal response): Movement of the bladder base in a cephalad and ventral direction toward the pubic bone infers contraction of the levator ani/puborectalis • No change • Descent: Movement of the bladder base caudal and posterior away from the pubic bone infers elevated intra-abdominal pressure—PFMs may be active but this cannot be confirmed *Bearing down:* Displacement of the bladder base during sustained increased intra-abdominal pressure: • Elevation • No change • Descent

Abbreviation: PFM, pelvic floor muscles.

[a]Factors that may compromise the measurement of bladder base displacement include: the lack of bony landmark as a fixed starting point and the fact that movement of the bladder base does not always reflect movement of the bladder neck.[137]

TABLE 14 Parameters and findings evaluated with trans-abdominal ultrasound imaging in the transverse plane

Parameters, specifications (units of measure) and measurement processes	Outputs and interpretation of findings
3.5.1.1.2 Symmetry of the bladder base: Equal curvature of bladder base with probe placed in the transverse plane **(NEW)**	*Rest:* Symmetrical or asymmetrical. Asymmetry can be related to unilateral increased tone, unilateral decreased tone, operator error in probe position, or asymmetry of passive support (e.g., unilateral ligament damage/trauma)[a]
3.5.1.1.3 Bladder base displacement[b]: See 3.5.1.1.1. Movement of the bladder base (in mm or cm) is used as a surrogate measure for activity of the PFM	*PFM contraction:* Displacement of the bladder base during attempted PFM contraction: • Elevation (normal response): Movement of the bladder base in a cephalad/ventral direction. No change • Descent: Movement of the bladder base in a caudal/dorsal direction *Bearing down:* Displacement of the bladder base during sustained increased intra-abdominal pressure: • Elevation • No change • Descent (normal response)

Abbreviation: PFM, pelvic floor muscles.

[a]This finding must be correlated with findings of other tests and signs (especially digital vaginal/rectal palpation) to determine reason for asymmetry.

[b]Factors that may affect the measurement of bladder base displacement include: the lack of boney landmark as a fixed starting point and the fact that movement of the bladder base does not always reflect movement of the bladder neck.[137]

subjects an over an extended period of time **(CHANGED)**.[11]

3.4 Electromyography (EMG): Is the recording of electrical potentials generated by the depolarization of muscle fiber membranes.[24] Investigators reporting PFM EMG studies should state the position of the patient, the recording equipment[23] and conditions used as summarized in Box 2. Nerve conduction studies, for example, pudendal nerve testing, are beyond the scope of this document.

Important considerations when interpreting EMG signals: Baseline and contractile sEMG amplitude is affected by properties of the electrode, configuration of electrodes, recording system, and patient/individual characteristics. Raw amplitude cannot be compared between individuals because the signal's amplitude is affected by many factors (e.g., cutaneous/mucosal tissue thickness, vaginal lubrication, positioning/direction of electrodes with respect to the muscle and muscle fibers, and properties of the detection system[114–116]). As a consequence, normalization of the sEMG amplitude is considered critical when comparing data across individuals.[117]

3.4.a Artifact: Extraneous information in the EMG signal from sources other than the target muscle, such as the environment (e.g., electromagnetic radiation) or other body functions. Artifact examples include movement or contact quality artifact, heart rate, skin electrode shear, and electrode bridging **(CHANGED)**.[24]

3.4.b Crosstalk: Muscle activity from nearby muscles that can contribute to the recorded EMG amplitude and be misinterpreted as PFM activation.[24,xiii]

3.4.1 Intramuscular EMG: Is a recording of motor unit action potentials using needle (concentric or monopolar) or wire electrodes inserted into muscles[75,119] **(CHANGED)**.[24] This is not typically used in clinical assessment. The electrodes can be inserted to assess the superficial (e.g., bulbocavernosus) and deep layers (e.g., levator ani) of the PFMs as well as the urethral and anal sphincters.[120] This assessment as a rule focuses on the motor units to investigate motor unit physiology and pathophysiology. Parameters evaluated with concentric needle EMG can be used to differentiate between normal, denervated, reinnervated and myopathic muscle[121,122] Quantitative EMG includes analysis such as the multi-motor unit potential analysis[122] and the interference pattern analysis (turns/zero crossing or amplitude).[122]

3.4.2 Surface electromyography (sEMG): Is a recording of motor unit action potentials using surface electrodes placed on the skin or mucosa close to the muscle of interest. Recordings are also used in assessment of the activation pattern/"behavior" (sometimes referred to as kinesiological electromyography) of a particular muscle during a defined activity.[121] sEMG requires electrodes placed on the skin of the perineum or inside the urethra, vagina or rectum **(CHANGED)**.[12,24] Parameters and findings evaluated with sEMG are

TABLE 15 Parameters and findings evaluated with perineal and introital ultrasound imaging assessed in the mid-sagittal plane using a 2D/4D transducer oriented longitudinally/sagittally

Parameters, specifications (units of measure) and measurement processes	Outputs and interpretation of findings
(a) Parameters and anatomical landmarks assessed in the mid-sagittal plane using a 2D/4D transducer oriented longitudinally (f)	
Bladder neck parameters: Measurement of bladder neck position **3.5.1.3.1 Bladder neck position**: Refers to the bladder neck position relative to the pubic symphysis (PS).[139] The position is analyzed in a horizontal (x-axis) and vertical position (y-axis) relative to a horizontal reference line (measured in mm or cm) **(NEW)** Specify if using: the infero-posterior margin (Figure 6),[140a] the lowest margin,[141] or the central axis (line drawn from the anterior to the posterior margin) of the PS (Figure 7)[142]; the middle of the proximal urethra for the internal meatus,[143] the anterior bladder neck[144] or equidistant points along the urethra from bladder neck to external urethral meatus[145]	*Rest:* Quantification of bladder neck position at rest from the horizontal and vertical distances from the PS[140,146] Resting position of the bladder neck was found to be higher after PFM training[145] *PFM contraction:* Cranio-ventral displacement of the bladder neck [18] measured as: a decrease in *x*-value and increase in y-value. The ventro-cranial displacement of the bladder neck is measured as displacement = $\sqrt{(\Delta x^2 + \Delta y^2)}$.[143,146] The higher the value, the greater the ventro-cranial displacement of the bladder neck (bladder neck lift), which reflects the lifting action of the PFM[143,147–149] *Bearing down:* On bearing down with the instruction to relax the PFM, the dorso-caudal displacement is measured at the point of maximal displacement during the manoeuvre.[146] As the proximal urethra descends, the *x*-value increases and the *y*-value decreases. The higher the value, the greater the dorso-caudal displacement of the bladder neck (bladder neck descent or mobility).[18,143,149] Higher mobility is observed in incontinent women
3.5.1.3.2 Angle γ (Gamma)/Pubo-urethral angle: Is the angle (in degrees) between the bladder neck and a line drawn from the anterior to the posterior margin of the pubic symphysis[150] **(NEW)** (see Figure 7)	*Rest:* Quantification of the angle at rest[151] *PFM contraction:* A change of the angle γ from rest to a maximal PFM contraction. A reduction of the angle is expected as the bladder neck displaces ventrally and caudally. *Bearing down:* Method to assess bladder neck descent/mobility.[150] A larger angle indicates a greater descent of the bladder neck,[140] which has been related to incontinence
3.5.1.3.3 Perineal body: Should appear as a triangular shaped, slightly hyperechoic (white) structure anterior to the anal sphincter[11]	Indicates if the integrity of the perineal body is normal or compromised.
3.5.1.3.4 Levator plate angle: The angle (in degrees) between a horizontal reference line at the level of the infero-posterior margin of the PS intersecting a line from the infero-posterior margin of the PS to the anorectal angle[146,152]**(NEW)** (see Figure 6)	*Rest:* Quantification of the levator angle at rest. Elevated levator plate angle may be indicative of increased tone in the PFM[148] *PFM contraction:* An increase of the levator plate angle in comparison to the angle at rest. Levator plate excursion is calculated by subtracting the angle at rest from the angle during contraction[148] *Bearing down:* A decrease of the levator plate angle in comparison to the angle at rest. Levator plate excursion is measured as per contraction, smaller angle is expected[146]
3.5.1.3.5 Levator hiatus length: The distance (mm or cm) between the infero-posterior margin of the pubic symphysis to the anorectal angle, representing the levator hiatus antero-posterior diameter in the mid-sagittal view[147,152] **(NEW)** (see Figure 6)	*Rest:* Quantification of the levator hiatus? at rest. Smaller levator plate length could be suggestive of high tone in PFM[148] *PFM contraction:* A reduction of the levator hiatus It has been demonstrated to reflect a PFM contraction[139,151] *Bearing down:* An increase of the levator plate length is expected
3.5.1.3.6 Anorectal angle: The angle (in degrees), formed by the longitudinal axis of the anal canal and the posterior rectal wall[11]	*Rest:* Quantification of the anorectal angle at rest. Smaller anorectal angle could be suggestive of increased tone in the PFM[148] *PFM Contraction:* A reduction in the anorectal angle during a PFM contraction. The excursion of the anorectal angle is calculated as the angle during contraction of the levator ani muscle minus the angle at rest. Larger excursion could be suggestive of stronger activation of the PFM[148,153,154] *Bearing down:* Widening of the anorectal angle is expected.[154] If absent, PFM dyssynergia may be present

(Continues)

TABLE 15 (Continued)

Parameters, specifications (units of measure) and measurement processes	Outputs and interpretation of findings
(b) Parameters and anatomical landmarks assessed in the mid-sagittal plane using a 2D transducer oriented longitudinally/sagittally (m)	
Displacement or position (in mm or cm) of anatomical landmarks are assessed to interpret activation of individual PFM[25,27] **3.5.1.3.7 Urethro-vesical junction**: The point of maximal inflection of a line drawn along the dorsal border of the urethra and the bladder neck[25,27] **(NEW)** **3.5.1.3.8 Anorectal junction**: The ventral-most point of a line drawn along the ventral aspect of the rectum at the anorectal junction **(NEW)**	For the displacement of the anatomical landmarks described below, the displacement during contraction and cough are measured in relation to the resting position values.[25,155] Movement of these landmarks has been correlated with activation of levator ani (puborectalis)[25] **For 3.5.1.3.7 and 3.5.1.3.8**: *Rest:* The position of these landmarks in the caudo-cranial and antero-posterior planes can be quantified relative to the dorsal pole of the PS at rest (see Figure 8). Lower resting position has been observed in incontinent men[155] *PFM contraction:* Cranio-ventral displacement is expected[25,156] *Cough:* Caudal-dorsal motion can be observed during the pressurization phase of cough due to levator ani muscle lengthening (probable eccentric contraction, but this cannot be confirmed from US imaging) during the phase when intra-abdominal pressure increases. This is followed by cranial-ventral displacement that occurs due to PFM shortening (concentric contraction)
3.5.1.3.9 Bulb of the penis: the dorsal-most point on a line drawn around the bulb of the corpus cavernosum penis (**NEW**)	*Contraction:* Cranio-ventral displacement is expected due to bulbocavernosus shortening[25,27,155] *Cough:* Cranio-ventral displacement is expected due to bulbocavernosus shortening[27]
3.5.1.3.10 Mid-urethra: A point on the ventral border of the membranous urethra that undergoes the greatest dorsal movement during contraction. This point is located within 2.5 mm either side of a line drawn between the dorsal pole of the pubic symphysis and the most dorsal aspect of the bulb of the penis **(NEW)** (see Figure 8)	*PFM contraction:* Dorsal displacement is expected due to striated urethral sphincter shortening[25,27] *Cough:* Dorsal displacement of the mid-urethra due to striated urethral sphincter shortening[25,27]
(c) Parameters and anatomical landmarks assessed in the axial plane using the 4D transducer oriented longitudinally (f)	
3.5.1.3.11 Hiatal dimensions: Cross-sectional area of the pelvic floor/levator hiatus, including antero-posterior and transverse distances[24] Measured in the plane of minimal hiatal dimensions.[18] A transverse view is obtained and the plane of minimal hiatal dimensions is identified by moving the field of view cranially and caudally until the distance between the hyperechogenic posterior aspect of the PS and the hyperechogenic anterior border of the pubovisceral muscle is at a minimum[157]	
3.5.1.3.11.1 Levator hiatus antero-posterior diameter: The distance (in mm or cm) delineated from the PS (anteriorly) to the edge of the of the puborectalis muscle (posteriorly) **(NEW)** **3.5.1.3.11.2 Levator hiatus left-right/latero-lateral/ transverse diameter**: Latero-lateral diameter of the levator hiatus (in mm or cm) in the plane of minimal hiatal dimensions. **(NEW)** The diameter from right to left is measured at the widest part, and perpendicular to the antero-posterior diameter[11,149] **3.5.1.3.11.3 Levator hiatus area**: Defined and measured as the area (in mm^2 or cm^2) bordered by the pubovisceral muscle, PS and inferior pubic ramus in the plane of minimal hiatal dimensions[149] **(NEW)**	Findings below apply to all measurements of hiatal dimensions. *Rest:* Quantification of the levator hiatus diameters/area at rest. Smaller diameter/area has been observed in women with pelvic pain and is may suggest increased tone in the PFM.[148] Conversely, a larger hiatus has been observed in women with pelvic organ prolapse *PFM contraction:* A reduction of the area/diameter is expected during a maximal PFM contraction. Hiatus reductions during contraction can be calculated as the percentage of change from baseline (i.e., levator hiatus narrowing = (levator hiatus at rest − levator hiatus at contraction)/levator hiatus at rest ×100)[148] *Bearing down:* An increase in the levator hiatus diameter/area is expected on bearing down with the instruction to relax the PFM.[157] The difference (or percentage of change) between the diameter at rest and on bearing down determines the degree of hiatal distension.[11] Higher distension has been observed in women with pelvic organ prolapse[158]

TABLE 15 (Continued)

Parameters, specifications (units of measure) and measurement processes	Outputs and interpretation of findings
3.5.1.3.12 Maximal levator ani muscle thickness: Is the maximum diameter of the levator ani muscle measured in two locations bilaterally (in mm or cm). **(NEW)** (see Figure 9). This is usually located 1–1.5 cm above the minimal levator hiatus dimension. Measured perpendicular to the presumed levator ani fiber direction[149,157] **3.5.1.3.13 Levator ani muscle cross-sectional area**: Is the area (in mm^2 or cm^2) delineated by tracing the outline of the levator ani muscle at the level of maximal muscle thickness **(NEW)**	Provides morphologic measurements of the muscle diameter and area at rest.[157] *Rest:* Increased thickness has been observed after PFM training.[159] Increased thickness may be indirectly related to strength[159]
3.5.1.3.14 Integrity of the anterior/medial fibers of the levator ani: To assess if a disruption or disconnection of the insertion is present, direct the patient to perform a PFM contraction, and identify the plane of minimal hiatal dimensions at maximal PFM contraction. Use this plane for tomographic ultrasound imaging of the puborectalis component of the levator ani, with an interslice interval of 2.5 mm[4] **(NEW)**	**3.5.1.3.14.1 Complete avulsion**[b] is diagnosed when the 3 central slices show a loss of integrity or defect in the anterior/medial fiber of the levator ani muscle on the inferior pubic ramus resulting in a levator-urethra gap[4]**(NEW)**. A gap of more than 2.5 cm has been suggested as an indicator of avulsion[160]**3.5.1.3.14.2 Partial avulsion**: Is diagnosed when at one or two of the 3 central slices show a loss of integrity/defect of the medial fiber of the levator ani muscle **(CHANGED)**[24]
3.5.1.3.15 Urethral sphincter volume: Ultrasound imaging of the urethral sphincter (morphometry of the rhabdosphincter).[18]**(NEW)** The internal sphincter volume (in mm^3 or cm^3) including the longitudinal smooth muscle and the lumen is seen as a hypoechoic (black) core whereas the external sphincter volume or the circular striated muscle of the rhabdosphincter is seen as a hyperechoic (white) ellipsoid structure[161–163]	Smaller sphincter volume is related to urinary incontinence severity[164] and urethral pressure.[163] PFM training results in increased sphincter volume[165]
(d) Parameters and anatomical landmarks assessed with tomographic ultrasound imaging plane using the 4D transducer oriented transversely	
3.5.1.3.16 Integrity of the anal sphincter complex: assessment of the internal and external anal sphincter to identify presence/absence of a defect (measured in degrees). **(NEW)** Using tomographic ultrasound imaging, the anal canal is visualized in the mid-sagittal plane and a set of 8 transverse slices is placed to encompass the entire external anal sphincter by locating one slice cranial to the external anal sphincter (at level of puborectalis, Slice 1) and another caudal to the internal anal sphincter (at level of subcutaneous part of external anal sphincter, Slice 8), leaving six slices to delineate the entire muscle (Slices 2–7) (see Figure 10). Interslice interval is varied depending on external anal sphincter dimensions[133,166]	*PFM contraction:* A "significant" defect is diagnosed if four out of these six slices show a defect in >30∘ of the circumference of the external anal sphincter.[4,166]

Abbreviations: *f,* females; *m,* males; MVC, maximum voluntary contraction; PFM, pelvic floor muscles; *PS,* pubic symphysis.

[a]The horizontal reference line drawn from antero-posterior margin or the lowest margin of the PS may be influenced by the angle of the transducer.

[b]Synonyms are puborectalis/pubovisceralis defects or injury.

described in Table 12. Several common parameters are illustrated in Figure 5.

3.5 Imaging: Refers to the process of creating images using high-energy modalities to allow visualization of body tissues. Imaging provides tissue-specific evaluation to identify if morphological properties (e.g., trauma or deficit) are present, which may relate to an individual's presenting symptoms.[24,75] In this document, we focus on ultrasound and MRI assessment and the terms related to PFM morphology and function, as well as the influence of other structures on PFM support and contractility investigated using these tools. It

TABLE 16 Parameters and findings evaluated with endovaginal ultrasound imaging

Parameters, specifications (units of measure) and measurement processes	Outputs and interpretation of findings
(a) Parameters and anatomical landmarks assessed in the sagittal plane (2D)	
3.5.1.4.1 Levator plate position: the distance (in mm or cm) between the levator plate and endovaginal probe[167] **(NEW)**	*Rest:* Quantification of the distance between the levator plate and the probe with the PFM at rest. *PFM contraction:* A reduction of the distance between the levator plate and the probe is expected during a maximal PFM contraction; may be called levator plate lift. A greater levator plate lift ratio (lift/rest × 100) detected by dynamic endovaginal sonography has been associated with higher PFM strength as determined by the Modified Oxford Scale[167]
3.5.1.4.2 Perineal body: See 3.5.1.3.3. The depth (antero-posterior diameter) and height (supero-inferior diameter) of the perineal body can be measured in mm or cm in this plane[11,168]	*Rest:* Visibility of the structure and biometric measurements are identified at rest; indicate if the perineal body is visible or not visible[168]
3.5.1.4.3 Anorectal angle: See 3.5.1.3.6.	*Rest:* Quantification of the anorectal angle at rest[169]
(b) Parameters and anatomical landmarks assessed in the axial plane (3D)	
3.5.1.4.4 Hiatal dimensions: measurements of the following parameters are taken in the place of minimal hiatal dimension,[49] as described in Table 17 **3.5.1.4.4.1: Hiatal antero-posterior diameter**: Antero-posterior diameter (in mm or cm) of the levator hiatus measured at the level of minimum dimension **(NEW)** **3.5.1.4.4.2 Hiatal transverse diameter**: The diameter (in mm or cm) from right to left is measured at the widest part, and perpendicular to antero-posterior diameter **(NEW)** **3.5.1.4.4.3 Hiatal area**: Defined and measured as the area (in mm^2 or cm^2) bordered by the pubovisceral muscle, PS, and inferior pubic ramus in the plane of minimal hiatal dimensions **(NEW)**	*Rest:* Quantification of the levator hiatus diameters/area at rest[49]
3.5.1.4.5 Levator ani thickness: Defined as the diameter of the levator ani muscle (in mm or cm) at the "9 o'clock" and "3 o'clock" positions[49] as described in Table 15 **(NEW)**	*Rest:* Provides morphologic measurements of the levator ani diameter.
3.5.1.4.6 Levator plate angle: The angle (in degrees) between the reference line and the plane of minimal levator hiatal dimensions/anorectal angle, identified via a multiplanar view[169] **(NEW)**	*Rest:* This angle quantifies the levator plate position in reference to the pubic bone and the perineal body[169]
3.5.1.4.7 Levator ani deficiency: Assessed from a 3D volume. Individual levator ani muscles are evaluated in their specific axial plane where the full length of muscle can be visualized[170,171] **(NEW)**	*Rest:* The muscles on each side for each subgroup are scored based on thickness and detachment from the pubic bone: • 0 = no defect • 1 = minimal defect with <50% muscle loss • 2 = major defect with >50% muscle loss • 3 = total absence of the muscle Significant levator ani deficiency is defined as a total score within the range of 12–18[170,171]
3.5.1.4.8 Perineal body: This anatomical structure is visualized as an ovoid-shaped, mixed echogenicity structure. The width (latero-lateral diameter) (in mm or cm) of the perineal body can be measured in the axial plane[168]	as per 3.5.1.3.3

Abbreviations: PFM, pelvic floor muscles; *PS,* pubic symphysis

TABLE 17 Parameters and findings evaluated with endoanal ultrasound imaging

Parameters, specifications (units of measure) and measurement processes	Outputs and interpretation of findings
3.5.1.5.1 Anal sphincter defect (or pathology): Assessment of the internal and external anal sphincters to identify presence/absence of a defect; observed in cross-sectional images of the anal sphincter. **(NEW)** This measure is obtained by a probe inserted into the anal canal to a depth of approximately 6 cm and gently withdrawn down the anal canal. The anal canal is divided into three levels of assessment in the axial plane referring to the following anatomical structures[11,172,173]: **i.** Proximal or lower level: corresponds to the subcutaneous part of the external anal sphincter where the internal anal sphincter is absent **ii.** Middle level: corresponds to the superficial part of the EAS (concentric band of mixed echogenicity), the conjoined longitudinal layer, the IAS (concentric hypoechoic ring), and the transverse superficial perinei muscles **iii.** Distal or upper level: the hyperechoic sling of the puborectal muscle and the complete ring of the internal anal sphincter are visualized[11] The probe should be rotated so that the anterior aspect of the anal canal is superior (12 o'clock) and left lateral is oriented right (3 o'clock) on the screen. The acquisition of a three-dimensional data volume (3D ultrasound) of the anal sphincter is also possible	Indicate if defect is present or absent

Abbreviations: EAS, external anal sphincter; IAS, internal anal sphincter.

is not within the scope of this document to describe imaging of organ structures.

Ultrasound imaging: Pelvic floor ultrasound imaging measures PFM morphology and function via trans-abdominal, trans-perineal, trans-vaginal and trans-anal placement of the transducer **(CHANGED)**.[12,43] This investigation applies diagnostic techniques taken in B-mode that use high-frequency sound waves to image internal structures. The image is formed by the differing reflection signals produced when a beam of sound waves is projected into the body and bounces back at interfaces between those structures. Ultrasound evaluation may be undertaken as:

3.5.1.a Two-dimensional (2D) ultrasound: The transducer sends and receives ultrasound waves in one anatomical plane. The reflected waves are used to generate gray scale images of structures in the field of view in this anatomical plane.

3.5.1.b Three-dimensional (3D) ultrasound: Creates volume data from multiple 2D images which are gathered by reflected waves at a variety of angles. Software integrates this information to create a single static 3D image.

3.5.1.c Four-dimensional (4D) ultrasound: Is similar to 3D US, but the image is repeated at intervals over time. This technique requires the use of a 3D/4D transducer and enables real-time visualization of 3D images.

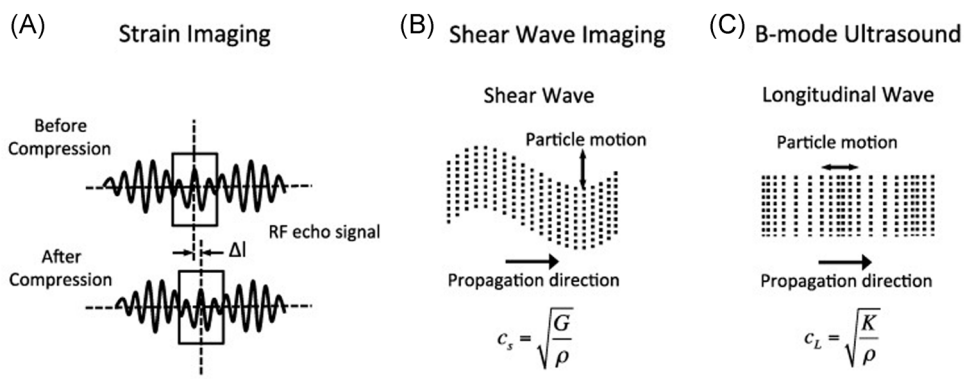

FIGURE 11 Ultrasound elastography physics, measurement methods (reproduced with permission from Sigrist et al.[174]). In strain imaging (A), tissue displacement is measured by correlation of radiofrequency echo signals between search windows (boxes) in the states before and after compression. In shear wave imaging (B), particle motion is perpendicular to the direction of wave propagation, with shear wave speed c_S related to shear modulus G. In B-mode ultrasound (C), particle motion is parallel to the direction of wave propagation, with longitudinal wave speed c_L related to bulk modulus K

TABLE 18 Parameters and findings evaluated with ultrasound elastography imaging

Parameters, specifications (units of measure) and measurement processes	Outputs and interpretation of findings
3.5.1.6.1 Shear wave elastography (SWE): Ultrasound elastography using shear waves generated by the US beam. ***(NEW)***. Different types are point SWE, 2D SWE, and transient elastography. 2D SWE uses an acoustic radiation force pulse sequence to generate shear waves, which propagate perpendicular to the ultrasound beam, causing transient displacements. The distribution of shear wave velocities at each pixel is directly related to the shear modulus in kilopascal (kPa), an absolute measure of the tissue's elastic properties. This technique is considered more objective than strain elastography[180]	Higher values indicate stiffer tissue, as shear waves propagate faster in stiffer tissues. Stiffness measures include both active (muscle contraction) and passive (viscoelastic properties) components of the tissue
3.5.1.6.1.1 Perineal shear wave elastography: Shear wave elastography applied per perineum. **(NEW).** Only 2D SWE has been applied to the PFM.[156,175,179] A linear transducer is placed against the perineum/vulva. Orientation is longitudinal (for assessing urethral sphincter), or aligned with the muscle fibers for specific PFM (e.g., puborectalis) assessment. A linear or curved transducer can be used. Stiffness is evaluated using quantitative shear modulus maps represented in a color-coded elastogram displaying shear-wave velocities in meters per second or tissue elasticity (shear elastic modulus) in kilopascals[181]	Higher values indicate stiffer tissue. Measures may provide evidence of stiffer tissue at rest (e.g., high activation of PFM at rest) and should increase with contraction.[156,175,179] Quality of measurement depends on orientation of the transducer (parallel with muscle fibers), accuracy of movement of the transducer to follow the movement of the muscle during contraction. Measures are compromised if there are areas in the image where the measure is saturated (stiffness greater than the measurable scale) or unable to be quantified by the system
3.5.1.6.2 Strain elastography: Ultrasound elastography which measures strain in one tissue area proportional to another. **(NEW).** Maps, or elastograms, are developed based on the relative differences in stiffness between the area of interest and the reference tissue. The assessor applies slight and constant vertical compression through the transducer along the major axis of the tissue. Elasticity is measured by means of the Young's modulus and is defined as the ratio between the pressure measured and the strain (deformation compared to the initial length) produced.[182] Soft tissue is more compressible than harder tissue and therefore has a higher strain (displacement) for the same applied stress (force). The results of strain elastography can only be expressed qualitatively or semi-quantitatively[180,182]	• **Qualitative analysis**: The different colors express different degrees of elasticity, usually varying from red (soft tissue) to blue (hard tissue) with intermediate colors representing intermediate degrees of stiffness[182] • **Semi-quantitative analysis**: the target tissue is selected and labeled as the region of interest (ROI) A, and the reference tissue is labeled as ROI B. Elasticity of tissue expressed as a strain ratio: B/A. The higher the value of B/A, the stiffer the target tissue
3.5.1.6.2.1 Pelvic floor strain elastography: strain elastography to assess deep PFM elasticity[176,177] and periurethral elasticity as an estimate of urethral mobility[183] (**NEW**) • To assess deep PFM: A perineal transducer is placed perpendicular to the skin in the sagittal plane to identify levator ani muscle. The levator ani muscle is selected on screen and labeled as the target tissue (region of interest [ROI] A), and the adjacent anal canal is selected and labeled as reference tissue (ROI B)[176] • To assess urethral support tissues: an endovaginal transducer is placed parallel to the urethral meatus. The target tissue is the tissue between the urethra and the vagina (para-urethral tissue) (ROI A), and the reference tissue is set at the level of the posterior tissue of the bladder neck (ROI B)	The higher the value of B/A, the stiffer the target tissue. A 4-point elasticity score has been used to represent levator ani muscle elasticity[176,177]

Abbreviations: PFM, pelvic floor muscles; ROI, region of interest; SWE, shear wave elastography.

TABLE 19 Parameters and findings evaluated with pelvic floor MRI

Parameters, specifications (units of measure) and measurement processes	Outputs and interpretation of findings
3.5.2.1 Levator ani defects: Is damage to muscle fibers ranging from disruption of a single fascicle, to complete disruption of the muscle origin **(CHANGED)**[24a] There is no universally accepted system for the diagnosis and evaluation of the extent of the injury. Essentially, abnormalities are judged to have occurred when the morphology of the pubococcygeal portion of the levator ani muscle deviates from what is seen in normal nulliparous women[24]	Levator ani damage on MRI can be diagnosed when one or more of the following is present: absence of pubococcygeal muscle fibers in at least one 4-mm section, or two or more adjacent 2-mm sections in both the axial and the coronal planes[24] Defect severity may be further scored in each muscle from 0 (no defect) to 3 (complete loss). A summed score for the two sides (0–6) is assigned and grouped as minor (0–3) or major (4–6)[11]
3.5.2.2 Levator ani position in the pelvis: Location of the levator ani in the sagittal plane in relation to defined landmarks and reference points/lines[146] **(NEW)**	May be normal, elevated, or descended[24]
3.5.2.3 Hiatal dimension: See 3.5.1.3.11	See 3.5.1.3.11
3.5.2.4 MR defecography: Demonstrates the anatomy of the anorectum as well as disorders of rectal evaluation. Barium paste is inserted before defecation over a translucent commode **(CHANGED)**[39]	This assessment focusses on anorectal function. When dyssynergia is diagnosed (see definition 4.3.1) this confirms PFM involvement[11]

Abbreviations: MRI, magnetic resonance imaging; PFM, pelvic floor muscles.
[a]The term levator injury is also used synonymously.[11,185]

3.5.1.d Tomographic ultrasound: Is viewing US imaging in sections. It allows the depiction of arbitrarily defined planes from volume data obtained in 3D or 4D US.[134,135]

Measurements are best understood by referring to anatomical planes of the body, that is, coronal (frontal), sagittal, and axial (horizontal or transverse) planes.

3.5.1.1 Trans-abdominal pelvic floor ultrasound: A 2D imaging technique to scan pelvic floor structures, using a convex transducer is placed in the supra-pubic region. (**NEW**) It can be oriented longitudinally to measure bladder base displacement in the mid-sagittal or parasagittal plane or oriented transversely to measure bladder base symmetry and displacement in the transverse plane. Trans-abdominal pelvic floor ultrasound is primarily used in clinical settings rather than for research purposes due to limitations measuring the image (no bony landmarks in view and difficulties for operator to keep transducer in plane—operator error is high). Artifact in measurement may also occur with incorrect PFM contraction when abdominal muscle contraction occurs (which pushes the transducer ventrally) and varying levels of bladder fullness (adherence to a fluid intake protocol may mitigate this limitation). Poor agreement between transverse and sagittal findings suggests measurement in the two planes evaluate displacement at different locations during a PFM contraction.[136] Table 13 describes the parameters and anatomical landmarks evaluated in the mid-sagittal plane, during different activity states of the PFM: rest, contraction and bearing down.

Parameters and findings evaluated with trans-abdominal imaging in the transverse plane—during different activity states of the PFM (rest, contraction, and bearing down)—are described in Table 14.

3.5.1.2 Introital pelvic floor ultrasound: 2D/3D/4D imaging technique to scan pelvic floor structures using an endocavity[xvi] transducer placed against the vaginal introitus/vulva or perineum.[4] **(NEW)** The transducer may be oriented ventrally/anteriorly to assess the pelvic floor structures (prolapse, levator ani muscle anatomy and function, and periurethral area), or oriented posteriorly to assess the anal sphincter structures.

3.5.1.3 Perineal pelvic floor ultrasound: 2D/3D/4D imaging technique to scan pelvic floor structures using a convex transducer placed against the perineum/vulva.[4] **(NEW)** The transducer may be oriented longitudinally/sagittally (for bladder neck/urethra, prolapse, and levator ani muscle assessment), or oriented transversely (for assessment of anal canal, sphincters). The terms transperineal and translabial ultrasound are both used to refer to perineal ultrasound. Parameters and findings evaluated with perineal and introital pelvic floor ultrasound—during different activity states of the PFM or actions (rest, contraction, and bearing down)—are presented in Table 15.

3.5.1.4 Endovaginal pelvic floor ultrasound: an endocavity transducer is inserted into the vagina (rotational mechanical probe or radial electronic probe)[4] to assess pelvic floor morphology. **(NEW)** It can be used to

TABLE 20 Parameters and findings evaluated with algometry

Parameters, specifications (units of measure) and measurement processes	Outputs and interpretation of findings
3.6.1 Algometer/Algesiometer: An instrument for measuring the pain response to a pressure stimulus. (**NEW**) An algometry device measures pressure applied in Newtons or kg/cm^2, with an associated patient-reported pain response • To assess vulval or vestibular pressure pain response, the assessor uses an algometer[186] or a syringe with a pre-loaded or pre-set amount of pressure, called a vulvalgesiometer[187] or a cotton swab[188] against the vulval tissue and delivers the pressure	Results may be expressed as the pressure applied when the patient reports detection or tolerance of pain, or a specific pressure applied and the patient rating of pain at that pressure. A finding of pain with a low applied pressure may suggest allodynia, and a finding of pain with a moderate applied pressure may suggest hyperalgesia Variability in readings can be caused by: anatomical test site (muscle belly vs. tendon[194]; mucosa vs. tendon,[191] coexistence of other pain disorders[195]; left vs. right,[196]) stage in menstrual cycle,[197] sex and gender,[198] rate of pressure increase during test, dimensions of the pressure applicator
• To assess intra-vaginal pressure pain response, the assessor mounts a digital palpometer (sensor) to the palpating digit, covered by examination glove, and connected to an algometry device. The device applies a pre-set amount of pressure to the tissue.[188–190] To assess pressure/pain in pelvic floor tissues, the assessor applies a pre-set amount of pressure (usually in the range of 0.5–2 N[188,191,192]), starting at a low pressure and assesses pain response to that pressure, or applying increasing amounts of pressure and instructing the patient to state when the pressure reaches the patient's threshold Algometry tests:	
• **3.6.1.1 Pressure pain threshold (PPT)**: The minimum intensity of a pressure stimulus that is perceived as painful.[193] (i.e., point at which a sensation changes from one of pressure to one of pain) (**NEW**) • **3.6.1.2 Pressure pain tolerance (PPTol)**: The highest intensity of painful pressure stimulus that an individual is able to tolerate[193] (**NEW**)	

evaluate bladder neck/urethra, levator ani muscle, anal canal, and sphincters during different activity states of the PFM (rest, contraction and bearing down), as described in Table 16.

3.5.1.5 Endoanal ultrasound (EAUS): An endocavity transducer is inserted into the anus (linear array 3600 3D transducer or radial array 3600 3D transducer).[4] **(NEW)** It can be used to assess the external anal sphincter (EAS) and internal anal sphincter (IAS). Parameters and findings evaluated with endoanal ultrasound imaging—during different activity states of the PFM (rest, contraction, and bearing down)—are described in Table 17.

3.5.1.6 Ultrasound elastography: A noninvasive imaging technique that allows quantification of mechanical and elastic tissue properties following application of physical stress.[174] **(NEW).** Elastography imaging uses either compression/strain elastography or shear-wave elastography.[156,175–179] The primary differences between elastography techniques relate to the type or source of applied stress, and the methods of detecting displacement of the examined structures. Comparison between the elastography types and B-mode ultrasound is shown in Figure 11.

Parameters and findings evaluated with ultrasound elastography imaging are described in Table 18.

3.5.2 Magnetic resonance imaging (MRI): Is a noninvasive diagnostic technique that produces computerized images of internal body tissues and is based on nuclear magnetic resonance of atoms within the body induced by the application of radio waves.[184] (**NEW**) This technique can be applied for many purposes in urology/gynecology/gastroenterology including the assessment of PFM injury, morphometry and positioning of the PFMs and related organs as well as anorectal functioning. Considering that MRI is rarely used in clinic to assess PFM morphometry and function, only a brief overview is provided in Table 19 and further details are available in other standardization documents.[11,150]

3.6 Algometry: A test to assess the pain response to application of blunt pressure. It is used to evaluate the pain threshold and pain tolerance. **(NEW)** Responses

TABLE 21 Criteria for diagnosis of pelvic floor tension myalgia

Assessment	Findings
Symptoms	• May relate to sensation of pain: pain, tender, ache, discomfort • May relate to sensation of increased tone: tight, tense, narrow or constricted
Signs	Tenderness or tender point on palpation of PFMs[a] per perineum, per vaginam, or per rectum as well one or more of the following signs: • Lack of perineal and/or PFM descent with sustained increased intra-abdominal pressure • Absent, partial or delayed relaxation of perineum and/or PFM after contraction • Nonrelaxing PFM • Hypertonicity, or increased PFM tone, on a continuum from transient increase in tone to spasm • Fasciculation • Reduced flexibility of the vaginal opening
Investigations	Muscle tenderness as assessed by digital algometry (palpometry) Finding of increased tone from any tool which measures tone (dynamometry, myotonometry, manometry, EMG, ultrasound or MRI) • if EMG reveals an inconsistent or elevated resting baseline, or slow de-recruitment, this suggests increased myoelectrical activity, which may be termed overactivity in the PFM[b]

Abbreviations: EMG, electromyography; MRI, magnetic resonance; PFM, pelvic floor muscles.

[a]When assessing sensory changes *PV* or *PR*, the clinician needs to determine whether s/he is detecting sensory change in the mucosa (mucosal sensitivity), or the underlying muscle (muscle tenderness) by differentiating the depth and firmness of palpation.

[b]The previously proposed term "overactive PFM"[23] has been used to refer to increased tone in a muscle, however if the source of the increased tone (contractile or noncontractile component of tone) cannot be determined, this term is not recommended.

may reflect increased sensitivity (allodynia, hyperalgesia, hyperpathia) or loss of sensation. Algometry does not provide objective information regarding pathology or neurophysiological function, as do other more sophisticated quantitative sensory testing methods.

Parameters and findings evaluated with algometry are described in Table 20.

5 | SECTION 4: DIAGNOSES

Diagnosis: The act or process of identifying or determining the nature and cause of a disease or injury through evaluation of patient history, examination, review of investigations, and the opinion derived from such an evaluation.[199]

TABLE 22 Criteria for diagnosis of pelvic floor myofascial pain syndrome

Assessment	Findings
Symptoms	Presence of pain
Signs	Tender point in a taut band (localized increased tone) of skeletal muscle[53,54] Patient pain recognition on tender point palpation Referral pattern Local twitch response The paired criteria of tender points in taut bands and predicted or recognized pain referral form the most frequently cited combination of diagnostic criteria
Investigations	There is no consensus regarding objective laboratory tests for myofascial trigger point diagnosis however MR elastography and ultrasound elastography have been reported to investigate myofascial taut bands[202] and trigger points[203] in the trapezius muscle

Abbreviation: MR, magnetic resonance

TABLE 23 Criteria for diagnosis of pelvic floor myalgia

Assessment	Findings
Symptoms	Pain, tender, ache, discomfort
Signs	Muscle tenderness or tender point on palpation of PFMs[a] and normal tone in PFM *per perineum*, *per vaginam*, or *per rectum*
Investigations	Muscle tenderness as assessed by digital algometry (palpometry)
	Finding of normal tone (measured by dynamometry, myotonometry, manometry, EMG, ultrasound, or MRI)

Abbreviations: EMG, electromyography; MRI, magnetic resonance imaging; PFM, pelvic floor muscles; *PR*, per rectum; PV, per vaginam.

[a]When assessing sensory changes *PV* or *PR*, the clinician needs to determine whether s/he is detecting sensory change in the mucosa (mucosal sensitivity), or the underlying muscle (muscle tenderness) by differentiating the depth and firmness of palpation.

TABLE 24 Criteria for diagnosis of decreased PFM tone

Assessment	Findings
Symptoms	Loose, lax, gaping, sagging, open, weak, bulging, full, loss of control
Signs	Hypotonicity, decreased PFM tone, anal or introital gaping, excessive flexibility of the vaginal opening, palpation of an anal sphincter gap or levator avulsion.
	Deficit in PFM contractile function: absence of voluntary PFM contraction, decreased strength (weakness), decreased sustained and repeated endurance, lack of perineal or PFM elevation, no urethral lift, partial or uncertain levator closure, small to no change in levator hiatus on contraction
Investigations	Any tool which measures tone (measured by dynamometry, myotonometry, manometry, EMG, ultrasound, or MRI)
	– If EMG reveals a reduced signal amplitude or peak microvolts, or shorter duration of sustained contraction this suggests decreased myoelectrical activity, which may be termed "underactivity" in the PFM[a]

Abbreviations: EMG, electromyography; MRI, magnetic resonance imaging; PFM, pelvic floor muscles.

[a]The previously proposed term "underactive PFM"[23] has been used to refer to decreased tone in a muscle, however, if the source of the decreased tone (contractile or noncontractile component of tone) cannot be determined, this term is not recommended.

TABLE 25 Criteria for diagnosis of vaginismus

Assessment	Findings
Symptoms	Pain, tight, tense, narrow, or constricted
Signs	Transient increased tone—inability to maintain relaxation with attempted vaginal penetration (*f*)
	Increased PFM tone
Investigations[a]	Assessment of resting tone (measured by dynamometry, myotonometry, manometry, EMG, ultrasound or MRI)
	Increased activation of PFM shown by perineal or peri-anal EMG during attempted vaginal penetration

Abbreviations: *f*, female; EMG, electromyography; MRI, magnetic resonance imaging; PFM, pelvic floor muscles.

[a]Investigations may be in-conclusive, as PFM tone values may overlap in conditions such as dyspareunia and vaginismus, therefore the PFM resting tone and response to attempted penetration may not exclusively diagnose vaginismus.

(CHANGED) The diagnostic process aims to identify the most specific disorder possible. Overarching diagnoses are used when there is less certainty about the presenting disorder. Diagnoses that are specific to the PFMs may coexist with and be used in addition to other pelvic floor diagnoses the patient presents with, for example, voiding dysfunction, pelvic organ prolapse. The diagnoses proposed below may change as evidence

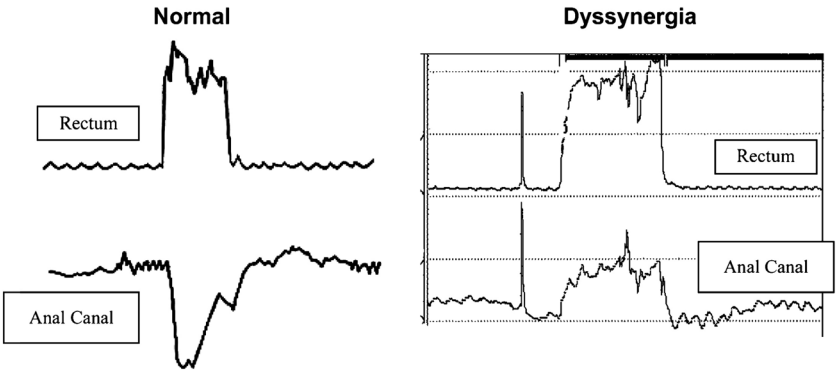

FIGURE 12 A normal and abnormal (dyssynergic) pattern of defecation (reproduced with permission from Rao[206]). A normal pattern consists of a rise in the intrarectal pressure coordinated with relaxation of anal sphincter pressure. In contrast, a dyssynergic pattern is associated with a paradoxical increase in anal sphincter pressure. Typical patterns for a normal and dyssynergic pattern of defecation as measured during anorectal manometry with a pressure sensor in the rectum and a pressure sensor in the anal canal

emerges to support or refute these terms as diagnostic terms. In some healthcare settings, clinicians are required to assign a code for the presenting diseases, disorders, injuries, and other related health conditions, using the International Classification of Diseases (ICD) coding system.[200] Not all terms below have a corresponding ICD diagnostic code. As advised by ICD, "codes that describe symptoms and signs, as opposed to diagnoses, are acceptable for reporting purposes when a related definitive diagnosis has not been established (confirmed) by the provider."

4.0. PFM disorder/dysfunction: An alteration of normal PFM function. **(NEW)** Any departure from normal function of the PFM that is of bother to the patient and has an associated sign and/or a finding from an investigation that suggests a departure from normal structure or function. If a specific disorder can be diagnosed, the following terms may be used.

TABLE 26 Criteria for diagnosis of anismus

Assessment	Findings
Symptoms	Pain, tender, ache, discomfort during attempted defecation or anal penetration
Signs	Perineal and/or PFM elevation with sustained increased IAP (bearing down) or attempted penetration
	Increased PFM tone
Investigations	Balloon expulsion test
	MR defecography
	EMG: PFM activation during defecation suggesting poor motor control[207]

Abbreviations: EMG, electromyography; IAP, intra-abdominal pressure; MR, magnetic resonance; PFM, pelvic floor muscles.

4.1 Disorder of increased PFM tone

4.1.1 Pelvic floor tension myalgia: A condition of pain and increased PFM tone **(NEW)**.[xv] If the location can be confirmed as the levator ani, then the term can be levator ani tension myalgia. Criteria for diagnosis of pelvic floor tension myalgia are described in Table 21.

4.1.2 Pelvic floor myofascial pain syndrome: A pelvic floor pain syndrome of myofascial origin. **(NEW)** this diagnosis has trigger points as a hallmark feature.[53] However there is no consensus of the definition and diagnostic criteria associated with trigger points.[53,54] The criteria most consistently used for diagnosis amongst researchers and expert clinicians are shown in Table 22.

4.2 Disorder of PFM pain

4.2.1 Pelvic floor myalgia: A condition of PFM pain. **(NEW).** Criteria for diagnosis of pelvic floor myalgia are described in Table 23.

4.3 Disorder of decreased PFM tone: A condition which results from a reduction in PFM tone, due to either the contractile or the noncontractile components of tone.[xvi] **(NEW)** Criteria for diagnosis of decreased PFM tone are described in Table 24.

4.4 Disorder of PFM coordination

4.4.1 PFM dyssynergia:[xvii] Paradoxical PFM or sphincter contraction: a dysfunction of coordination between the PFM and a functional activity, such as a PFM contraction when relaxation is functionally required. **(NEW)** These dyssynergias may share similar symptoms and signs.[xviii,xix]

4.4.1.1 Vaginismus: Spasm of vaginal musculature that interferes with vaginal penetration **(CHANGED)**.[12,xx] Criteria for diagnosis of vaginismus are described in Table 25.

TABLE 27 Criteria for diagnosis of pudendal neuralgia

Assessment	Findings
Symptoms	Pain in the distribution of the pudendal nerve and its referral areas, primarily the genitalia including the vulvovaginal, anorectal, and distal urethral areas Worse in the sitting position Pain does not wake the patient at night, no numbness of the perineum The patient may also have associated pelvic floor symptoms[208]
Signs	Nantes criteria[209] sign: No loss of sensation in the pudendal distribution on objective testing Other signs include: • Tenderness to palpation anywhere along the length of the pudendal nerve • Increased tone and tenderness of the obturator internus or piriformis muscles (depending on the location of the nerve irritation) • Positive pudendal nerve neurodynamic test • Positive pudendal nerve provocation test
Investigations	As per Nantes criteria[209]: may be confirmed by relief of patient's pain after a pudendal nerve block with or without guided imaging[a]

[a]Pudendal nerve blocks are technically difficult to perform accurately and lack of pain relief after the procedure does not rule out the condition.[208]

Vaginismus may also be termed genito-pelvic pain/penetration disorder, which includes fear or anxiety as a component of the disorder.[204,205]

4.4.1.2 Anismus: Spasm of the EAS with attempted defecation or anal penetration **(CHANGED)**.[11,xxi] This dyssynergia is shown in Figure 12.

Criteria for diagnosis of anismus are described in Table 26.

4.5 Pudendal neuralgia: Pudendal neuralgia is a chronic and severely disabling neuropathic pain syndrome caused by mechanical or nonmechanical injury of the pudendal nerve.[208] **(NEW)** The Nantes criteria list five essential diagnostic criterion including three symptoms, one sign and one investigation.[209] These criteria are described in Table 27.

6 | CONCLUSION

This report has drawn together the most frequently published methods of PFM assessment that appear in the published literature. This process has highlighted the plethora of terms in current use. We have attempted to provide the most precise yet clinically meaningful definitions and descriptions of these terms, and where available, provided an explanation of the finding from the assessment method. We hope this will provide clinicians and researchers with clarity and standardization in the recording of PFM function and dysfunction. It is anticipated that some of these terms will be discarded over time and new terms will emerge, and a revision of this document will be required in the future. It is important to remember that visual observation and digital palpation are subjective forms of assessment, and the assessor must be aware that conclusions of PFM function or dysfunction based on these clinical observations may be uncertain. At present, PFM tone and involuntary action remain less well understood than properties such as strength. Where available, the use of quantitative assessment tools (investigations), may strengthen the certainty of the finding. In some instances, it may not be possible to identify a specific classification of PFM disorder, beyond the first level of diagnosis of "PFM disorder."

7 | AREAS FOR FURTHER RESEARCH

A core outcome set for PFM assessment would be valuable, however, this requires knowledge of the clinimetric properties of the many assessment methods currently used in clinical practice and research, and a comparison of these properties amongst the assessment methods; such knowledge is lacking. There is an urgent need for a report to compile the validity, reliability, and

responsiveness of PFM assessment methods, especially for the more subjective methods of visual observation and digital palpation. The clinimetric properties of some aspects of the more objective methods of PFM assessment (simple and sophisticated tools) has been undertaken, however many gaps in testing remain. Whether any of these assessment methods provide diagnostic test accuracy of PFM function and dysfunction is unknown. Future research in this area is required.

ACKNOWLEDGMENTS

We thank the following individuals for their contributions to this document: Paul McCrory, Neurologist, Ph.D., Melbourne, Australia; Paul Hodges, Physiotherapist, Ph.D., Brisbane, Australia; Ryan Stafford, Ph.D., Brisbane, Australia; Dawson Kidgell, Neuromuscular Physiologist, Ph.D., Melbourne, Australia; Ashlyn Frazer, Human Physiologist, Ph.D., Melbourne, Australia; Hans Peter Dietz, Urogynaecologist, Ph.D., Sydney, Australia; Irmina Nahon, Physiotherapist, Ph.D., Canberra, Australia; Patricia Neumann, Physiotherapist, Ph.D., Adelaide, Australia; Shaza Kadah, Physiotherapist, Ph.D. student, Melbourne, Australia. This document has involved 20 rounds of reviews of individual sections and 12 rounds of full manuscript review by working group members, with cochair checking, collation, and feedback of all comments. Additional multiple rounds of development and refinement were undertaken by the cochairs in-between section and full working group reviews. The process was subject to live Meetings in Florence (September 2017), Philadelphia (2018), and Gothenburg (2019). Comprehensive and constructive review was undertaken by expert external reviewers, and we thank them for their considered input: Bert Messelink, David Vodusek, Chantale Dumoulin, Margaret Sherburn, Paul Hodges, and MJ Strauhal. A further round of revisions was undertaken in response to the external review. Following ICS website publication, there was a further round of review to address membership comments. Version 12 will be submitted for website and NAU journal publication.

CONFLICT OF INTERESTS

Mohammad S. Rahnama'i: Consultant for Bioness, Dr. Pfleger, Astellas and Janssen. Marijke Slieker-ten Hove: KOL Indiba. The remaining authors declare that there are no conflict of interests.

ENDNOTES

[i]For complete assessment, include as indicated: posture, abdominal, spinal, functional.

[ii]"Vaginal flatus" is the term used by Sultan[11], however, Neels[13] distinguishes vaginal "wind" from vaginal "flatus"; assigning the term flatus to wind that is passed through the vagina due to an enterovaginal fistula. This type of "vaginal wind" will not be odorless. The term 'vaginal flatus' is more likely to be used by the clinician, not the patient.

[iii]This symptom is called "flatus incontinence" by Sultan et al.[11]

[iv]Included in the physical examination may be the use of simple tools, such as a pin, cotton wool, reflex hammer, and so forth.

[v]When assessing sensory changes *PV* or *PR*, the clinician needs to determine whether s/he is detecting sensory change in the mucosa (mucosal sensitivity), or the underlying muscle (muscle tenderness) by attempting to differentiate the depth and firmness of palpation.

[vi]Depth of insertion of examining finger has been described for *per vaginam* assessment.[16]

[vii]Terms such as short or elevated PFM may not be discernible via digital palpation and are therefore not recommended as sign terms.

[viii]If the spasm is painful, this is usually described as a muscle cramp.

[ix]This term refers to simple manometry that measures pressure in the anal sphincter. This is differentiated from sophisticated anorectal manometry—see Section 3.3.2.

[x]This investigation is termed "anal manometry" in Sultan et al.[11]

[xi]This is not an exhaustive list of anorectal manometry parameters.

[xii]Clinical EMG devices mainly offer preset filter settings.

[xiii]Reducing the size of electrode and the interelectrodeinterelectrode distance may increase the system selectivity and reduce crosstalk.[118]

[xvi]An endocavity probe consists of an elongated probe used to perform endovaginal or endorectal examination.

[xv]This term was first used by Sinaki et al.,[201] however, in their case series, they did not assess PFM tone or tension. Nevertheless, they proposed the cause of the pain was "habit contraction or chronic spasm of the PFM." We propose that this term should be used only when both pain and increased tone are present.

[xvi]It may be impossible to distinguish between the two subsets of this condition without access to an investigation which is able to separate the measurement of the contractile from the non-contractile components of tone. Even so, the certainty of the contribution from the contractile component of tone recorded by sEMG needs to consider the limitations of sEMG findings (noise, cross-talk, etc.).

[xvii]Dyssynergia may be similar to the condition termed "overactive pelvic floor muscles" as described by Messelink et al.[23]: "A situation in which the pelvic floor muscles do not relax, or may even contract when relaxation is functionally needed for example during micturition or defecation. This condition is based on symptoms such as voiding problems, obstructed defecation, or dyspareunia and on signs like the absence of voluntary pelvic floor muscle relaxation."

[xviii]PFM-related symptoms reported by patients may be secondary to more bothersome functional symptoms such as inability to void, defaecate or allow vaginal entry.

[xix]Difficulty voiding may be due to paradoxical contraction of the urethral sphincter, as occurs in conditions such as detrusor

sphincter dyssynergia or voiding dysfunction, however, there is no hallmark PFM-related symptom that the patient reports.

[xx]As stated in Rogers et al.,[12] there is often (phobic) avoidance and anticipation/fear/experience of pain, along with variable involuntary PFM contraction. Patients with vaginismus could present with severe fear avoidance without vulvar pain or fear avoidance with vulvar pain. Structural or other physical abnormalities must be ruled out/addressed. There is controversy of whether or not this term should be retained, with the Diagnostic and Statistical Manual of Mental Disorders 2013 proposal to replace dyspareunia and vaginismus with the term "Genito-Pelvic Pain/Penetration Disorder (GPP/PD),"[204] and the lack of consensus on this term.[205]

[xxi]Anismus is the PFM component of dyssynergic defecation. Diagnosis of dyssynergic defecation includes functional constipation criteria, prolonged transit, and ineffective motility to expel feces.[206]

ORCID

Helena Frawley http://orcid.org/0000-0002-7126-6979
Melanie Morin http://orcid.org/0000-0002-7171-1411
Stéphanie Bernard http://orcid.org/0000-0003-1454-8555
Doreen McClurg http://orcid.org/0000-0002-2872-1702
Mohammad S. Rahnama'i https://orcid.org/0000-0003-1953-7441

REFERENCES

1. Eizenberg N, Anatomedia, McGraw-Hill E. An@tomedia: a new approach to medical education, developments in anatomy. In: *Anatomedia Online. Richmond, VIC: Anatomedia Pty Ltd*. North Ryde, NSW: McGraw-Hill Education; 2010.
2. Primal Pictures L. *Primal Pictures' 3D real time*. London: Primal Pictures; 2018.
3. Frawley HC, Neumann P, Delany C. An argument for competency-based training in pelvic floor physiotherapy practice. *Physiother Theory Pract*. 2019;35(12):1117-1130.
4. AIUM/IUGA. AIUM/IUGA practice parameter for the performance of Urogynecological ultrasound examinations: developed in collaboration with the ACR, the AUGS, the AUA, and the SRU. *Int Urogynecol J*. 2019;30(9):1389-1400.
5. Saltiel F, Miranda-Gazzola APG, Vitoria RO, Figueiredo EM. Terminology of pelvic floor muscle function in women with and without urinary incontinence: a systematic review. *Phys Ther*. 2018;98(10):876-890.
6. WHO. *International Classification of Functioning, Disability, and Health: ICF*. Geneva: World Health Organization; 2001. https://www.who.int/classifications/icf/en/
7. Saltiel F, Miranda-Gazzola APG, Vitoria RO, Sampaio RF, Figueiredo EM. Linking pelvic floor muscle function terminology to the international classification of functioning, disability and health. *Phys Ther*. 2020;100:1659-1680.
8. FDA. Food and Drug administration guidance for industry on patient-reported outcome measures: use in medical product development to support labeling claims. In: *Federal Register*. Vol 74. Silver Spring, MD; 2009:1-43.
9. Johnston B, Patrick D, Devji T, et al. Chapter 18: Patient-reported outcomes. In: Higgins J, Thomas J, Chandler J et al. eds. *Cochrane Handbook for Systematic Reviews of Interventions version 6.0 (updated July 2019)*. Cochrane; 2019.
10. Melzack R. The short-form McGill Pain Questionnaire. *Pain*. 1987;30(2):191-197.
11. Sultan AH, Monga A, Lee J, et al. An International Urogynecological Association (IUGA)/International Continence Society (ICS) joint report on the terminology for female anorectal dysfunction. *Neurourol Urodyn*. 2017;36(1):10-34.
12. Rogers RG, Pauls RN, Thakar R, et al. An International Urogynecological Association (IUGA)/International Continence Society (ICS) joint report on the terminology for the assessment of sexual health of women with pelvic floor dysfunction. *Neurourol Urodyn*. 2018;37(4):1220-1240.
13. Neels H, Mortiers X, de Graaf S, Tjalma WAA, De Wachter S, Vermandel A. Vaginal wind: a literature review. *Eur J Obstet Gynecol Reprod Biol*. 2017;214:97-103.
14. Bottomley JM. *Quick Reference Dictionary for Physical Therapy*. 3rd ed. Thorofare: Slack; 2013.
15. Slieker-ten Hove MC, Pool-Goudzwaard AL, Eijkemans MJ, Steegers-Theunissen RP, Burger CW, Vierhout ME. Face validity and reliability of the first digital assessment scheme of pelvic floor muscle function conform the new standardized terminology of the International Continence Society. *Neurourol Urodyn*. 2009;28(4):295-300.
16. Shelly B, Dunbar A. Palpation and assessment of the pelvic floor muscles using depth and positional measurements. *J Sec Womens Health*. 2004;28(1):19-23.
17. Slade SC, Dionne CE, Underwood M, Buchbinder R. Consensus on Exercise Reporting Template (CERT): explanation and elaboration statement. *Br J Sports Med*. 2016;50(23):1428-1437.
18. Haylen BT, Maher CF, Barber MD, et al. An International Urogynecological Association (IUGA)/International Continence Society (ICS) joint report on the terminology for female pelvic organ prolapse (POP). *Neurourol Urodyn*. 2016;35(2):137-168.
19. Geller EJ, Robinson BL, Matthews CA, et al. Perineal body length as a risk factor for ultrasound-diagnosed anal sphincter tear at first delivery. *Int Urogynecol J*. 2014;25(5):631-636.
20. Lane TL, Chung CP, Yandell PM, Kuehl TJ, Larsen WI. Perineal body length and perineal lacerations during delivery in primigravid patients. *Proc (Bayl Univ Med Cent)*. 2017;30(2):151-153.
21. Ambrose S, Keighley MR. Outpatient measurement of perineal descent. *Ann R Coll Surg Engl*. 1985;67(5):306-308.
22. Mazier WP. Keyhole deformity. Fact and fiction. *Dis Colon Rectum*. 1985;28(1):8-10.
23. Messelink B, Benson T, Berghmans B, et al. Standardization of terminology of pelvic floor muscle function and dysfunction: report from the pelvic floor clinical assessment group of the International Continence Society. *Neurourol Urodyn*. 2005;24(4):374-380.
24. Bø K, Frawley HC, Haylen BT, et al. An International Urogynecological Association (IUGA)/International Continence Society (ICS) joint report on the terminology for the conservative and nonpharmacological management of female pelvic floor dysfunction. *Neurourol Urodyn*. 2017;36(2):221-244.

25. Stafford RE, Coughlin G, Lutton NJ, Hodges PW. Validity of estimation of pelvic floor muscle activity from transperineal ultrasound imaging in men. *PLOS One*. 2015;10(12): e0144342.
26. Neumann PB, O'Callaghan M. The role of preoperative puborectal muscle function assessed by transperineal ultrasound in urinary continence outcomes at 3, 6, and 12 months after robotic-assisted radical prostatectomy. *Int Neurourol J*. 2018;22(2):114-122.
27. Stafford RE, van den Hoorn W, Coughlin G, Hodges PW. Postprostatectomy incontinence is related to pelvic floor displacements observed with trans-perineal ultrasound imaging. *Neurourol Urodyn*. 2018;37(2):658-665.
28. Baessler K, Metz M, Junginger B. Valsalva versus straining: there is a distinct difference in resulting bladder neck and puborectalis muscle position. *Neurourol Urodyn*. 2017;36(7): 1860-1866.
29. Oettle GJ, Roe AM, Bartolo DC, Mortensen NJ. What is the best way of measuring perineal descent? A comparison of radiographic and clinical methods. *Br J Surg*. 1985;72(12):999-1001.
30. Savoye-Collet C, Savoye G, Koning E, Leroi AM, Dacher JN. Gender influence on defecographic abnormalities in patients with posterior pelvic floor disorders. *World J Gastroenterol*. 2010;16(4):462-466.
31. Henry MM. Anorectal physiology and pelvic floor disorders. *Curr Opin Gastroenterol*. 1986;2(1):44-46.
32. Miller JM, Ashton-Miller JA, DeLancey JO. A pelvic muscle precontraction can reduce cough-related urine loss in selected women with mild SUI. *J Am Geriatr Soc*. 1998;46(7):870-874.
33. Slieker-ten Hove M, Pool-Goudzwaard A, Eijkemans M, Steegers-Theunissen R, Burger C, Vierhout M. Pelvic floor muscle function in a general population of women with and without pelvic organ prolapse. *Int Urogynecol J*. 2010;21(3): 311-319.
34. IASP. *IASP Terminology, in Part III: Pain Terms, A Current List with Definitions and Notes on Usage, Classification of Chronic Pain*. 2nd ed. 1994, 2nd update 2012 ed. https://www.iasp-pain.org/Education/Content.aspx?ItemNumber=1698%26navItemNumber=5762011. Accessed January 24, 2020.
35. Fearmonti R, Bond J, Erdmann D, Levinson H. A review of scar scales and scar measuring devices. *Eplasty*. 2010;10:e43.
36. Farrar JT, Young JP, LaMoreaux L, Werth JL, Poole RM. Clinical importance of changes in chronic pain intensity measured on an 11-point numerical pain rating scale. *Pain*. 2001;94(2):149-158.
37. Butler D. *The Sensitive Nervous System, ch 5, Neurodynamics*. Adelaide: Noigroup Publications; 2000.
38. Previnaire JG. The importance of the bulbocavernosus reflex. *Spinal Cord Ser Cases*. 2018;4:2.
39. D'Ancona C, Haylen B, Oelke M, et al. The International Continence Society (ICS) report on the terminology for adult male lower urinary tract and pelvic floor symptoms and dysfunction. *Neurourol Urodyn*. 2019;38(2):433-477.
40. Skorupska E, Bednarek A, Samborski W. Tender points and trigger points—differences and similarities. *J Musculoskelet Pain*. 2013;21(3):269-275.
41. Strauhal MJ, Frahm J, Morrison P, et al. Vulvar. pain: a comprehensive review. *J Womens Health Phys Ther*. 2007; 31(3):7-26.
42. Bergeron S, Binik YM, Khalife S, Pagidas K, Glazer HI. Vulvar vestibulitis syndrome: reliability of diagnosis and evaluation of current diagnostic criteria. *Obstet Gynecol*. 2001;98(1):45-51.
43. Doggweiler R, Whitmore KE, Meijlink JM, et al. A standard for terminology in chronic pelvic pain syndromes: a report from the chronic pelvic pain working group of the international continence society. *Neurourol Urodyn*. 2017;36(4): 984-1008.
44. Popeney C, Ansell V, Renney K. Pudendal entrapment as an etiology of chronic perineal pain: diagnosis and treatment. *Neurourol Urodyn*. 2007;26(6):820-827.
45. Apte G, Nelson P, Brismee JM, Dedrick G, Justiz R, Sizer PS. Chronic female pelvic PainuPart 1: clinical pathoanatomy and examination of the pelvic region. *Pain Pract*. 2012;12(2):88-110.
46. Neumann P, Sutherland P, Nahon I, Morrison S. Pelvic floor muscle training after prostate surgery. *Lancet*. 2012; 379(9811):119; author reply 121.
47. Gentilcore-Saulnier E, McLean L, Goldfinger C, Pukall CF, Chamberlain S. Pelvic floor muscle assessment outcomes in women with and without provoked vestibulodynia and the impact of a physical therapy program. *J Sex Med*. 2010;7(2 Pt 2): 1003-1022.
48. Dietz HP. The quantification of levator muscle resting tone by digital assessment. *Int Urogynecol J*. 2008;19(11): 1489-1493.
49. van Delft K, Shobeiri SA, Thakar R, Schwertner-Tiepelmann N, Sultan AH. Intra- and interobserver reliability of levator ani muscle biometry and avulsion using three-dimensional endovaginal ultrasonography. *Ultrasound Obstet Gynecol*. 2014;43(2):202-209.
50. Allen D, Widener G. Tone abnormalities. In: Cameron M, ed., *Physical Agents in Rehabilitation: From Research to Practice*. 3rd ed. St. Louis, MO: Saunders Elsevier; 2009:78.
51. Simons DG, Mense S. Understanding and measurement of muscle tone as related to clinical muscle pain. *Pain*. 1998; 75(1):1-17.
52. Masi AT, Hannon JC. Human resting muscle tone (HRMT): narrative introduction and modern concepts. *J Bodyw Mov Ther*. 2008;12(4):320-332.
53. Tough EA, White AR, Richards S, Campbell J. Variability of criteria used to diagnose myofascial trigger point pain syndrome—evidence from a review of the literature. *Clin J Pain*. 2007;23(3):278-286.
54. Bourgaize S, Janjua I, Murnaghan K, Mior S, Srbely J, Newton G. Fibromyalgia and myofascial pain syndrome: two sides of the same coin? A scoping review to determine the lexicon of the current diagnostic criteria. *Musculoskeletal Care*. 2019;17(1):3-12.
55. Kavvadias T, Pelikan S, Roth P, Baessler K, Schuessler B. Pelvic floor muscle tenderness in asymptomatic, nulliparous women: topographical distribution and reliability of a visual analogue scale. *Int Urogynecol J*. 2013;24(2):281-286.
56. Devreese A, Staes F, De Weerdt W, et al. Clinical evaluation of pelvic floor muscle function in continent and incontinent women. *Neurourol Urodyn*. 2004;23(3):190-197.
57. Reissing ED, Binik YM, Khalife S, Cohen D, Amsel R. Vaginal spasm, pain, and behavior: an empirical investigation of the diagnosis of vaginismus. *Arch Sex Behav*. 2004;33(1):5-17.

58. Lance JW, McLeod JG. *A Physiological Approach to Clinical Neurology*. 3rd ed. London; Boston, MA: Butterworths; 1981.
59. National Institute of Neurological Disorders and Stroke (NINDS). Dystonia. https://www.ninds.nih.gov/Disorders/Patient-Caregiver-Education/Fact-Sheets/Dystonias-Fact-Sheet. Accessed 27 September 27, 2020.
60. Rao SSC. Rectal Exam: Yes, it can and should be done in a busy practice! *Am J Gastroenterol*. 2018;113(5):635-638.
61. Bo K, Finckenhagen HB. Vaginal palpation of pelvic floor muscle strength: inter-test reproducibility and comparison between palpation and vaginal squeeze pressure. *Acta Obstet Gynecol Scand*. 2001;80(10):883-887.
62. Deegan EG, Stothers L, Kavanagh A, Macnab AJ. Quantification of pelvic floor muscle strength in female urinary incontinence: a systematic review and comparison of contemporary methodologies. *Neurourol Urodyn*. 2018;37(1):33-45.
63. Van Kampen M, De Weerdt W, Feys H, Honing S. Reliability and validity of a digital test for pelvic muscles strength in women. *Neurourol and Urodynam*. 1996;15:338-336.
64. Laycock J, Jerwood D. Pelvic floor muscle assessment: the PERFECT scheme. *Physiotherapy*. 2001;87(12):631-642.
65. Brink CA, Sampselle CM, Wells TJ, Diokno AC, Gillis GL. A digital test for pelvic muscle strength in older women with urinary incontinence. *Nurs Res*. 1989;38(4):196-199.
66. Draper N, Marshall H. *Exercise Physiology for Health and Sports Performance*. 1st ed. Abingdon, Oxon: Routledge; 2012:206.
67. Plowman D, Smith D. *Exercise Physiology for Health, Fitness, and Performance*. Philadelphia. PA: Wolters Kluwer Health/Lippincott Williams & Wilkins Health; 2014.
68. Schabrun SM, Stafford RE, Hodges PW. Anal sphincter fatigue: is the mechanism peripheral or central? *Neurourol Urodyn*. 2011;30(8):1550-1556.
69. Milios JE, Ackland TR, Green DJ. Pelvic floor muscle training in radical prostatectomy: a randomized controlled trial of the impacts on pelvic floor muscle function and urinary incontinence. *BMC Urol*. 2019;19(1):116.
70. Kent M. *The Oxford Dictionary of Sports Science & Medicine*. 3rd ed. Oxford: Oxford University Press Print Publication; 2006.
71. Boyles SH, Edwards SR, Gregory WT, Denman MA, Clark AL. Validating a clinical measure of levator hiatus size. *Am J Obstet Gynecol*. 2007;196(2):174 e171-174 e174.
72. Keshwani N, McLean L. State of the art review: Intravaginal probes for recording electromyography from the pelvic floor muscles. *Neurourol Urodyn*. 2015;34(2):104-112.
73. Barbosa PB, Franco MM, Souza Fde O, Antonio FI, Montezuma T, Ferreira CH. Comparison between measurements obtained with three different perineometers. *Clinics (Sao Paulo)*. 2009;64(6):527-533.
74. Dumoulin C, Gravel D, Bourbonnais D, Lemieux MC, Morin M. Reliability of dynamometric measurements of the pelvic floor musculature. *Neurourol Urodyn*. 2004;23(2):134-142.
75. Castro Dias D, Robinson D, Bosch R, et al. Initial assessment of urinary incontinence in adult male and female patients. In: Abrams P, Cardoso L, Wagg A, Wein A, eds., *Incontinence, 6th International Consultation on Incontinence*. Tokyo: ICUD ICS; 2017:2619.
76. Caufriez M. Approche globale et technique analytique. In: Caufriez M, *Postpartum et rééducation urodynamique*. Vol Tome 3. Brussels: Collection Maïte; 1993:36-44.
77. Miller JM, Ashton-Miller JA, Perruchini D, DeLancey JO. Test-retest reliability of an instrumented speculum for measuring vaginal closure force. *Neurourol Urodyn*. 2007;26(6):858-863.
78. Dumoulin C, Bourbonnais D, Lemieux MC. Development of a dynamometer for measuring the isometric force of the pelvic floor musculature. *Neurourol Urodyn*. 2003;22(7):648-653.
79. Morin M, Dumoulin C, Gravel D, Bourbonnais D, Lemieux MC. Reliability of speed of contraction and endurance dynamometric measurements of the pelvic floor musculature in stress incontinent parous women. *Neurourol Urodyn*. 2007;26(3):397-403. discussion 404.
80. Parezanovic-Ilic K, Jevtic M, Jeremic B, Arsenijevic S. [Muscle strength measurement of pelvic floor in women by vaginal dynamometer]. *Srp Arh Celok Lek*. 2009;137(9-10):511-517.
81. Kruger JA, Nielsen PM, Budgett SC, Taberner AJ. An automated hand-held elastometer for quantifying the passive stiffness of the levator ani muscle in women. *Neurourol Urodyn*. 2015;34(2):133-138.
82. Nunes FR, Martins CC, Guirro EC, Guirro RR. Reliability of bidirectional and variable-opening equipment for the measurement of pelvic floor muscle strength. *PM R*. 2011;3(1):21-26.
83. Romero-Culleres G, Peña Pitarch E, Jane, Feixas C, et al. Reliability and validity of a new vaginal dynamometer to measure pelvic floor muscle strength in women with urinary incontinence. *Neurourol Urodyn*. 2013;32:658-659.
84. Morin M, Gravel D, Bourbonnais D, Dumoulin C, Ouellet S. Reliability of dynamometric passive properties of the pelvic floor muscles in postmenopausal women with stress urinary incontinence. *Neurourol Urodyn*. 2008;27(8):819-825.
85. Morin M, Gravel D, Bourbonnais D, Dumoulin C, Ouellet S, Pilon JF. Application of a new method in the study of pelvic floor muscle passive properties in continent women. *J Electromyogr Kinesiol*. 2010;20(5):795-803.
86. Morin M, Binik YM, Bourbonnais D, Khalife S, Ouellet S, Bergeron S. Heightened pelvic floor muscle tone and altered contractility in women with provoked vestibulodynia. *J Sex Med*. 2017;14(4):592-600.
87. Gajdosik RL. Passive extensibility of skeletal muscle: review of the literature with clinical implications. *Clin Biomech*. 2001;16:87-101.
88. Magnusson SP. Passive properties of human skeletal muscle during stretch maneuvers. A review. *Scand J Med Sci Sports*. 1998;8(2):65-77.
89. Agyapong-Badu S, Warner M, Samuel D, Narici M, Cooper C, Stokes M. Anterior thigh composition measured using ultrasound imaging to quantify relative thickness of muscle and non-contractile tissue: a potential biomarker for musculoskeletal health. *Physiol Meas*. 2014;35(10):2165-2176.
90. Aird L, Samuel D, Stokes M. Quadriceps muscle tone, elasticity and stiffness in older males: reliability and symmetry using the MyotonPRO. *Arch Gerontol Geriatr*. 2012;55(2):e31-e39.

91. Bailey L, Dinesh S, Warner M, Stokes M. Parameters representing muscle tone, elasticity and stiffness of biceps brachii in healthy older males: Symmetry and within-session reliability using the MyotonPRO. *J Neurol Disord*. 2013;1(16).
92. Myoton AS. *MyotonPro User Manual*. Myoton Muscle Diagnostics. Tallinn; 2018.
93. Agyapong-Badu S, Warner M, Samuel D, Stokes M. Practical considerations for standardized recording of muscle mechanical properties using a myometric device: Recording site, muscle length, state of contraction and prior activity. *J Musculoskelet Res*. 2018;21(2):13.
94. Rosier PFWM, Schaefer W, Lose G, et al. International Continence Society Good Urodynamic Practices and Terms 2016: urodynamics, uroflowmetry, cystometry, and pressure-flow study. *Neurourol Urodyn*. 2017;36(5):1243-1260.
95. Frawley HC, Galea MP, Phillips BA, Sherburn M, Bo K. Reliability of pelvic floor muscle strength assessment using different test positions and tools. *Neurourol Urodyn*. 2006; 25(3):236-242.
96. Hundley AF, Wu JM, Visco AG. A comparison of perineometer to brink score for assessment of pelvic floor muscle strength. *Am J Obstet Gynecol*. 2005;192(5):1583-1591.
97. Bo K, Kvarstein B, Hagen R, Larsen S. Pelvic floor muscle exercises for the treatment of female stress urinary incontinence: II. Validity of vaginal pressure measurements of pelvic floor muscle strength and the necessity of supplementary methods for control of correct contraction. *Neurourol Urodyn*. 1990;9:479-487.
98. Bump RC, Mattiasson A, Bø K, et al. The standardization of terminology of female pelvic organ prolapse and pelvic floor dysfunction. *Am J Obstet Gynecol*. 1996;175(1):10-17.
99. Ribeiro Jdos S, Guirro EC, Franco Mde M, Duarte TB, Pomini JM, Ferreira CH. Inter-rater reliability study of the Peritron perineometer in pregnant women. *Physiother Theory Pract*. 2016;32(3):209-217.
100. Braekken IH, Majida M, Engh ME, Bo K. Are pelvic floor muscle thickness and size of levator hiatus associated with pelvic floor muscle strength, endurance and vaginal resting pressure in women with pelvic organ prolapse stages I-III? A cross sectional 3D ultrasound study. *Neurourol Urodyn*. 2014; 33(1):115-120.
101. Friedman S, Blomquist JL, Nugent JM, McDermott KC, Munoz A, Handa VL. Pelvic muscle strength after childbirth. *Obstet Gynecol*. 2012;120(5):1021-1028.
102. Rahmani N, Mohseni-Bandpei MA. Application of perineometer in the assessment of pelvic floor muscle strength and endurance: a reliability study. *J Bodyw Mov Ther*. 2011;15(2): 209-214.
103. Sigurdardottir T, Steingrimsdottir T, Arnason A, Bo K. Test-retest intra-rater reliability of vaginal measurement of pelvic floor muscle strength using Myomed 932. *Acta Obstet Gynecol Scand*. 2009;88(8):939-943.
104. Ferreira CH, Barbosa PB, de Oliveira Souza F, Antonio FI, Franco MM, Bo K. Inter-rater reliability study of the modified Oxford Grading Scale and the Peritron manometer. *Physiotherapy*. 2011;97(2):132-138.
105. Quartly E, Hallam T, Kilbreath S, Refshauge K. Strength and endurance of the pelvic floor muscles in continent women: an observational study. *Physiotherapy*. 2010;96(4):311-316.
106. Batista EM, Conde DM, Do Amaral WN, Martinez EZ. Comparison of pelvic floor muscle strength between women undergoing vaginal delivery, cesarean section, and nulliparae using a perineometer and digital palpation. *Gynecol Endocrinol*. 2011;27(11):910-914.
107. Bo K, Constantinou C. Reflex contraction of pelvic floor muscles during cough cannot be measured with vaginal pressure devices. *Neurourol Urodyn*. 2011;30(7):1404.
108. Deffieux X, Raibaut P, Rene-Corail P, et al. External anal sphincter contraction during cough: not a simple spinal reflex. *Neurourol Urodyn*. 2006;25(7):782-787.
109. Vollebregt PF, Rasijeff AMP, Pares D, et al. Functional anal canal length measurement using high-resolution anorectal manometry to investigate anal sphincter dysfunction in patients with fecal incontinence or constipation. *Neurogastroenterol Motil*. 2019;31(3):e13532.
110. Carrington EV, Scott SM, Bharucha A, et al. Expert consensus document: advances in the evaluation of anorectal function. *Nat Rev Gastroenterol Hepatol*. 2018;15(5):309-323.
111. Broens PMA, Penninckx FM, Ochoa JB. Fecal continence revisited: the anal external sphincter continence reflex. *Dis Colon Rectum*. 2013;56(11):1273-1281.
112. Zbar AP, Aslam M, Gold DM, Gatzen C, Gosling A, Kmiot WA. Parameters of the rectoanal inhibitory reflex in patients with idiopathic fecal incontinence and chronic constipation. *Dis Colon Rectum*. 1998;41(2):200-208.
113. JElectKin_Recommendations. Standards for reporting EMG data. *J Electromyogr Kinesiol*. 2017;34(suppl C):I-II.
114. Clancy EA, Negro F, Farina D. Single-channel techniques for information extraction from the surface EMG signal. In: Merletti R, Farina D, eds. *Surface Electromyography: Physiology, Engineering and Applications*. Hoboken, NJ: John Wiley & Sons, Incorporated; 2016:731.
115. Vigotsky AD, Halperin I, Lehman GJ, Trajano GS, Vieira TM. Interpreting signal amplitudes in surface electromyography studies in sport and rehabilitation sciences. *Front Physiol*. 2017;8:985.
116. Enoka RM, Duchateau J. Inappropriate interpretation of surface EMG signals and muscle fiber characteristics impedes understanding of the control of neuromuscular function. *J Appl Physiol (1985)*. 2015;119(12):1516-1518.
117. Disselhorst-Klug C, Schmitz-Rode T, Rau G. Surface electromyography and muscle force: limits in sEMG-force relationship and new approaches for applications. *Clin Biomech (Bristol, Avon)*. 2009;24(3):225-235.
118. Farina D, Stegeman DF, Merletti R. Biophysics of the generation of EMG signals. In: Merletti R, Farina D, eds. *Surface Electromyography: Physiology, Engineering and Applications*. Hoboken, NJ: John Wiley & Sons, Incorporated; 2016:731.
119. Merletti R, Farina D. Analysis of intramuscular electromyogram signals. *Philos Trans A Math Phys Eng Sci*. 2009; 367(1887):357-368.
120. Podnar S, Vodusek DB. Protocol for clinical neurophysiologic examination of the pelvic floor. *Neurourol Urodyn*. 2001; 20(6):669-682.
121. Vodusek DB. Electromyography. In: Bo K, Berghmans B, Morkved S, Van Kampen M eds., *Evidence-Based Physical Therapy for the Pelvic Floor*. 2nd ed. Edinburgh: Churchill Livingstone; 2015.

122. Bianchi F, Squintani GM, Osio M, et al. Neurophysiology of the pelvic floor in clinical practice: a systematic literature review. *Funct Neurol*. 2017;22(4):173-193.
123. Smith MD, Coppieters MW, Hodges PW. Postural response of the pelvic floor and abdominal muscles in women with and without incontinence. *Neurourol Urodyn*. 2007;26(3):377-385.
124. Moser H, Leitner M, Baeyens JP, Radlinger L. Pelvic floor muscle activity during impact activities in continent and incontinent women: a systematic review. *Int Urogynecol J*. 2018;29(2):179-196.
125. Brueckner D, Kiss R, Muehlbauer T. Associations between practice-related changes in motor performance and muscle activity in healthy individuals: a systematic review. *Sports Med Open*. 2018;4(1):9.
126. Dewaele P, Deffieux X, Villot A, Billecocq S, Amarenco G, Thubert T. Effect of body position on reflex and voluntary pelvic floor muscle contraction during a distraction task. *Neurourol Urodyn*. 2018;37:2695-2701.
127. McCrary JM, Ackermann BJ, Halaki M. EMG amplitude, fatigue threshold, and time to task failure: a meta-analysis. *J Sci Med Sport*. 2017.
128. Mohseni Bandpei MA, Rahmani N, Majdoleslam B, Abdollahi I, Ali SS, Ahmad A. Reliability of surface electromyography in the assessment of paraspinal muscle fatigue: an updated systematic review. *J Manipulative Physiol Ther*. 2014;37(7):510-521.
129. Glazer HI, Romanzi L, Polaneczky M. Pelvic floor muscle surface electromyography. Reliability and clinical predictive validity. *J Reprod Med*. 1999;44(9):779-782.
130. Basmajian JV. New views on muscular tone and relaxation. *Can Med Assoc*. 1957;77:203-205.
131. Clemmesen S. Some studies on muscle tone. *Proc R Soc Med*. 1951;44(8):637-646.
132. Stafford RE, Ashton-Miller JA, Constantinou CE, Hodges PW. Novel insight into the dynamics of male pelvic floor contractions through transperineal ultrasound imaging. *J Urol*. 2012;188(4):1224-1230.
133. Guzman Rojas RA, Kamisan Atan I, Shek KL, Dietz HP. Anal sphincter trauma and anal incontinence in urogynecological patients. *Ultrasound Obstet Gynecol*. 2015;46(3):363-366.
134. Dietz HP. Quantification of major morphological abnormalities of the levator ani. *Ultrasound Obstet Gynecol*. 2007;29(3):329-334.
135. Dietz HP, Shek KL. Tomographic ultrasound imaging of the pelvic floor: which levels matter most? *Ultrasound Obstet Gynecol*. 2009;33(6):698-703.
136. Sherburn M, Murphy CA, Carroll S, Allen TJ, Galea MP. Investigation of transabdominal real-time ultrasound to visualise the muscles of the pelvic floor. *Aust J Physiother*. 2005;51(3):167-170.
137. Thompson JA, O'Sullivan PB, Briffa K, Neumann P, Court S. Assessment of pelvic floor movement using transabdominal and transperineal ultrasound. *Int Urogynecol J*. 2005;16(4):285-292.
138. Bo K, Sherburn M, Allen T. Transabdominal ultrasound measurement of pelvic floor muscle activity when activated directly or via a transversus abdominis muscle contraction. *Neurourol Urodyn*. 2003;22(6):582-588.
139. Dietz H, Hoyte L, Steensma A. *Atlas of pelvic floor ultrasound*. London: Springer-Verlag London Limited; 2008.
140. Dietz HP. Pelvic floor ultrasound: a review. *Clin Obstet Gynecol*. 2017;60(1):58-81.
141. Lone F, Sultan AH, Stankiewicz A, Thakar R. Interobserver agreement of multicompartment ultrasound in the assessment of pelvic floor anatomy. *Br J Radiol*. 2016;89(1059):20150704.
142. Schaer G. The clinical value of sonographic imaging of the urethrovesical anatomy. *Scand J Urol Nephrol Suppl*. 2001;35(207):80-86; discussion 106-125.
143. Dietz HP, Wilson PD, Clarke B. The use of perineal ultrasound to quantify levator activity and teach pelvic floor muscle exercises. *Int Urogynecol J*. 2001;12(3):166-168. discussion 168-169.
144. Reddy AP, DeLancey JO, Zwica LM, Ashton-Miller JA. On-screen vector-based ultrasound assessment of vesical neck movement. *Am J Obstet Gynecol*. 2001;185(1):65-70.
145. Shek KL, Dietz HP. The urethral motion profile: a novel method to evaluate urethral support and mobility. *Aust N Z J Obstet Gynaecol*. 2008;48(3):337-342.
146. Majida M, Braekken IH, Umek W, Bo K, Saltyte Benth J, Ellstrom Engh M. Interobserver repeatability of three- and four-dimensional transperineal ultrasound assessment of pelvic floor muscle anatomy and function. *Ultrasound Obstet Gynecol*. 2009;33(5):567-573.
147. Thibault-Gagnon S, Auchincloss C, Graham R, McLean L. The temporal relationship between activity of the pelvic floor muscles and motion of selected urogenital landmarks in healthy nulliparous women. *J Electromyogr Kinesiol*. 2018;38:126-135.
148. Morin M, Bergeron S, Khalife S, Mayrand MH, Binik YM. Morphometry of the pelvic floor muscles in women with and without provoked vestibulodynia using 4D ultrasound. *J Sex Med*. 2014;11(3):776-785.
149. Braekken IH, Majida M, Ellstrom-Engh M, Dietz HP, Umek W, Bo K. Test-retest and intra-observer repeatability of two-, three- and four-dimensional perineal ultrasound of pelvic floor muscle anatomy and function. *Int Urogynecol J*. 2008;19(2):227-235.
150. Haylen BT, de Ridder D, Freeman RM, et al. An International Urogynecological Association (IUGA)/International Continence Society (ICS) joint report on the terminology for female pelvic floor dysfunction. *Neurourol Urodyn*. 2010;29(1):4-20.
151. Dietz HP, Jarvis SK, Vancaillie TG. The assessment of levator muscle strength: a validation of three ultrasound techniques. *Int Urogynecol J*. 2002;13(3):156-159.
152. Braekken IH, Majida M, Engh ME, Bo K. Test-retest reliability of pelvic floor muscle contraction measured by 4D ultrasound. *Neurourol Urodyn*. 2009;28(1):68-73.
153. Costantini S, Esposito F, Nadalini C, et al. Ultrasound imaging of the female perineum: the effect of vaginal delivery on pelvic floor dynamics. *Ultrasound Obstet Gynecol*. 2006;27(2):183-187.
154. Beer-Gabel M, Teshler M, Barzilai N, et al. Dynamic transperineal ultrasound in the diagnosis of pelvic floor disorders: pilot study. *Dis Colon Rectum*. 2002;45(2):239-245; discussion 245-238.
155. Stafford RE, Coughlin G, Hodges PW. Comparison of dynamic features of pelvic floor muscle contraction between

men with and without incontinence after prostatectomy and men with no history of prostate cancer. *Neurourol Urodyn*. 2020;39(1):170-180.
156. Aljuraifani R, Stafford RE, Hug F, Hodges PW. Female striated urogenital sphincter contraction measured by shear wave elastography during pelvic floor muscle activation: Proof of concept and validation. *Neurourol Urodyn*. 2018; 37(1):206-212.
157. Dietz HP, Shek C, Clarke B. Biometry of the pubovisceral muscle and levator hiatus by three-dimensional pelvic floor ultrasound. *Ultrasound Obstet Gynecol*. 2005;25(6):580-585.
158. Dietz HP, Shek C, De Leon J, Steensma AB. Ballooning of the levator hiatus. *Ultrasound Obstet Gynecol*. 2008;31(6): 676-680.
159. Braekken IH, Majida M, Engh ME, Bo K. Morphological changes after pelvic floor muscle training measured by 3-dimensional ultrasonography: a randomized controlled trial. *Obstet Gynecol*. 2010;115(2 Pt 1):317-324.
160. Dietz HP, Abbu A, Shek KL. The levator-urethra gap measurement: a more objective means of determining levator avulsion? *Ultrasound Obstet Gynecol*. 2008;32(7):941-945.
161. Digesu GA, Robinson D, Cardozo L, Khullar V. Three-dimensional ultrasound of the urethral sphincter predicts continence surgery outcome. *Neurourol Urodyn*. 2009;28(1):90-94.
162. Ismail S, Morin M, Tu LM. Assessment of the effects of autologous muscle derived cell injections on urethral sphincter morphometry using 3D/4D ultrasound. *World J Urol*. 2020; 38:2881-2889.
163. Robinson D, Toozs-Hobson P, Cardozo L, Digesu A. Correlating structure and function: three-dimensional ultrasound of the urethral sphincter. *Ultrasound Obstet Gynecol*. 2004; 23(3):272-276.
164. Athanasiou S, Khullar V, Boos K, Salvatore S, Cardozo L. Imaging the urethral sphincter with three-dimensional ultrasound. *Obstet Gynecol*. 1999;94(2):295-301.
165. Madill SJ, Pontbriand-Drolet S, Tang A, Dumoulin C. Changes in urethral sphincter size following rehabilitation in older women with stress urinary incontinence. *Int Urogynecol J*. 2015;26(2):277-283.
166. Dietz HP. Exoanal imaging of the anal sphincters. *J Ultrasound Med*. 2018;37(1):263-280.
167. Rostaminia G, Peck J, Quiroz L, Shobeiri SA. Levator plate upward lift on dynamic sonography and levator muscle strength. *J Ultrasound Med*. 2015;34(10):1787-1792.
168. Santoro GA, Shobeiri SA, Petros PP, Zapater P, Wieczorek AP. Perineal body anatomy seen by three-dimensional endovaginal ultrasound of asymptomatic nulliparae. *Colorectal Dis*. 2016;18(4):400-409.
169. Shobeiri SA, Rostaminia G, White D, Quiroz L. The determinants of minimal levator hiatus and their relationship to the puborectalis muscle and the levator plate. *BJOG*. 2013; 120(2):205-211.
170. Rostaminia G, Manonai J, Leclaire E, et al. Interrater reliability of assessing levator ani deficiency with 360° 3D endovaginal ultrasound. *Int Urogynecol J*. 2014;25(6):761-766.
171. Rostaminia G, Peck JD, Quiroz LH, Shobeiri SA. Characteristics associated with pelvic organ prolapse in women with significant levator ani muscle deficiency. *Int Urogynecol J*. 2016;27(2):261-267.
172. Thakar R, Sultan AH. Anal endosonography and its role in assessing the incontinent patient. *Best Pract Res Clin Obstet Gynaecol*. 2004;18(1):157-173.
173. Abdool Z, Sultan AH, Thakar R. Ultrasound imaging of the anal sphincter complex: a review. *Br J Radiol*. 2012;85(1015): 865-875.
174. Sigrist RMS, Liau J, Kaffas AE, Chammas MC, Willmann JK. Ultrasound elastography: review of techniques and clinical applications. *Theranostics*. 2017;7(5):1303-1329.
175. Stafford RE, Aljuraifani R, Hug F, Hodges PW. Application of shear-wave elastography to estimate the stiffness of the male striated urethral sphincter during voluntary contractions. *BJU Int*. 2017;119(4):619-625.
176. Xie M, Feng Y, Zhang XY, Hua KQ, Ren YY, Wang WP. Evaluation of pelvic floor muscle by transperineal elastography in patients with deep infiltrating endometriosis: preliminary observation. *J Med Ultrason*. 2019;46(1):123-128.
177. Xie M, Zhang XY, Liu J, Ding JX, Ren YY, Hua KQ. Evaluation of levator ani with no defect on elastography in women with POP. *Int J Clin Exp Med*. 2015;8(6):10204-10212.
178. Gachon B, Nordez A, Pierre F, Fradet L, Fritel X, Desseauve D. In vivo assessment of the levator ani muscles using shear wave elastography: a feasibility study in women. *Int Urogynecol J*. 2019;30(7):1179-1186.
179. Morin M, Salomoni S, Stafford R, Hall L, Hodges PW. Validation of shear-wave elastography for evaluating pelvic floor muscle stiffness. *Neurourol Urodyn*. 2019;38(S3):436-438.
180. Paluch L, Nawrocka-Laskus E, Wieczorek J, Mruk B, Frel M, Walecki J. Use of ultrasound elastography in the assessment of the musculoskeletal system. *Pol J Radiol*. 2016;81:240-246.
181. Taljanovic MS, Gimber LH, Becker GW, et al. Shear-wave elastography: basic physics and musculoskeletal applications. *Radiographics*. 2017;37(3):855-870.
182. Fabio la Torre M, Magarelli N, Cipriani A, et al. Applications of ultrasound elastography in musculoskeletal imaging: technical aspects and review of the literature. *Curr Med Imaging Rev*. 2017;13(3):251-259.
183. Kreutzkamp JM, Schaefer SD, Amler S, Strube F, Kiesel L, Schmitz R. Strain elastography as a new method for assessing pelvic floor biomechanics. *Ultrasound Med Biol*. 2017;43(4): 868-872.
184. Merriam-Webster. Merriam-Webster Online Dictionary. http://www.merriam-webster.com/dictionary/. Accessed March 26, 2020.
185. Bo K, Frawley HC, Haylen BT, et al. An International Urogynecological Association (IUGA)/International Continence Society (ICS) joint report on the terminology for the conservative and nonpharmacological management of female pelvic floor dysfunction. *Int Urogynecol J*. 2017;28(2): 191-213.
186. Cyr MP, Bourbonnais D, Pinard A, Dubois O, Morin M. Reliability and convergent validity of the algometer for vestibular pain assessment in women with provoked vestibulodynia. *Pain Med*. 2016;17(7):1220-1228.
187. Pukall CF, Young RA, Roberts MJ, Sutton KS, Smith KB. The vulvalgesiometer as a device to measure genital pressure-pain threshold. *Physiol Meas*. 2007;28(12):1543-1550.
188. Zolnoun D, Bair E, Essick G, Gracely R, Goyal V, Maixner W. Reliability and reproducibility of novel methodology for

assessment of pressure pain sensitivity in pelvis. *J Pain*. 2012; 13(9):910-920.

189. Loving S, Thomsen T, Jaszczak P, Nordling J. Pelvic floor muscle dysfunctions are prevalent in female chronic pelvic pain: a cross-sectional population-based study. *Eur J Pain*. 2014;18(9):1259-1270.
190. Tu FF, Fitzgerald CM, Kuiken T, Farrell T, Norman, Harden R. Vaginal pressure-pain thresholds: Initial validation and reliability assessment in healthy women. *Clin J Pain*. 2008;24(1): 45-50.
191. Witzeman K, Nguyen RHN, Eanes A, As-Sanie S, Zolnoun D. Mucosal versus muscle pain sensitivity in provoked vestibulodynia. *J Pain Res*. 2015;8:549-555.
192. Meister MR, Sutcliffe S, Ghetti C, et al. Development of a standardized, reproducible screening examination for assessment of pelvic floor myofascial pain. *Am J Obstet Gynecol*. 2019;220(3):255.e1-255.e9.
193. IASP. IASP Terminology, updated from Part III. December 14, 2017. https://www.iasp-pain.org/Education/Content.aspx?ItemNumber=1698#Painthreshold2017. Accessed February 24, 2020.
194. Ohrbach R, Gale EN. Pressure pain thresholds in normal muscles—reliability, measurement effects, and topographic differences. *Pain*. 1989;37(3):257-263.
195. Sanses TVD, Chelimsky G, McCabe NP, et al. The pelvis and beyond: musculoskeletal tender points in women with chronic pelvic pain. *Clin J Pain*. 2016;32(8):659-665.
196. Park G, Kim CW, Park SB, Kim MJ, Jang SH. Reliability and usefulness of the pressure pain threshold measurement in patients with myofascial pain. *Ann Rehabil Med Arm*. 2011; 35(3):412-417.
197. Rezaii T, Hirschberg AL, Carlstrom K, Ernberg M. The influence of menstrual phases on pain modulation in healthy women. *J Pain*. 2012;13(7):646-655.
198. Chesterton LS, Barlasb P, Foster NE, Baxter GD, Wright CC. Gender differences in pressure pain threshold in healthy humans. *Pain*. 2003;101(3):259-266.
199. Medical Dictionary. The free dictionary. http://medical-dictionary.thefreedictionary.com/. Accessed February 5, 2020.
200. ICD. ICD codes. https://www.cdc.gov/nchs/data/icd/10cmguidelines-FY2020_final.pdf. Accessed February 5, 2020.
201. Sinaki M, Merritt JL, Stillwell GK. Tension myalgia of the pelvic floor. *Mayo Clin Proc*. 1977;52(11):717-722.
202. Chen Q, Bensamoun S, Basford JR, Thompson JM, An KN. Identification and quantification of myofascial taut bands with magnetic resonance elastography. *Arch Phys Med Rehabil*. 2007;88(12):1658-1661.
203. Sikdar S, Shah JP, Gebreab T, et al. Novel applications of ultrasound technology to visualize and characterize myofascial trigger points and surrounding soft tissue. *Arch Phys Med Rehabil*. 2009;90(11):1829-1838.
204. DSMMD. *Diagnostic and Statistical Manual of Mental Disorders: DSM-5*. 5th ed. Arlington, VA: American Psychiatric Association; 2013.
205. Parish SJ, Cottler-Casanova S, Clayton AH, McCabe MP, Coleman E, Reed GM. The evolution of the female sexual disorder/dysfunction definitions, nomenclature, and classifications: a review of DSM, ICSM, ISSWSH, and ICD. *Sex Med Rev*. 2021;9:36-56.
206. Rao SSC, Patcharatrakul T. Diagnosis and treatment of dyssynergic defecation. *J Neurogastroenterol Motil*. 2016;22(3): 423-435.
207. Rao SSC. Constipation: evaluation and treatment of colonic and anorectal motility disorders. *Gastroenterol Clin North Am*. 2007;36(3):687-711.
208. Kaur J, Singh P. *Pudendal Nerve Entrapment Syndrome*. Treasure Island: StatPearls Publishing; 2019. https://www.ncbi.nlm.nih.gov/books/NBK544272/
209. Labat JJ, Riant T, Robert R, Amarenco G, Lefaucheur JP, Rigaud J. Diagnostic criteria for pudendal neuralgia by pudendal nerve entrapment (Nantes criteria). *Neurourol Urodyn*. 2008;27(4):306-310.

How to cite this article: Frawley H, Shelly B, Morin M, et al. An International Continence Society (ICS) report on the terminology for pelvic floor muscle assessment. *Neurourol Urodyn*. 2021; 1-44. https://doi.org/10.1002/nau.24658